

IONING OUT THE DIAGNOSIS IN CHRONIC DIARRHOEA

ep68

D I Campbell, M Ognjanovic, H L Smith, J Clarke, S Watson, S Court

Arch Dis Child Educ Pract Ed 2005;90:ep68–ep73. doi: 10.1136/adc.2004.069203

A 7 month old boy called Grant presented to his general practitioner (GP) with discomfort when feeding and diarrhoea. He had been initially breast fed, but this was discontinued after several weeks and formula milk was introduced, with no change to his symptoms. His GP made a presumptive diagnosis of cow's milk intolerance and advised a change to a soya based milk; he also referred him to a general paediatrician at his local district general hospital.

The paediatrician agreed that cow's milk intolerance was the most likely diagnosis and prescribed a whey hydrolysate, which Grant refused to drink, and then Neocate (amino acid based milk substitute), which he tolerated. Nevertheless, the diarrhoea (two semi-formed stools per day), vomiting, and "pains" on feeding continued, although he appeared well nourished with his weight on the 91st centile and height on the 75th centile. Since the symptoms had persisted, the following investigations were ordered: blood count (normal), renal function (normal), serum IgA (normal) and endomesial antibodies (negative), and radioallergosorbent tests (RAST, negative). An oesophageal pH study was also organised.

The paediatrician knew that allergies to cow's milk in the absence of immediate symptoms (urticaria, bronchospasm, profuse diarrhoea) are likely to be non-IgE mediated and therefore RAST test negative. The paediatrician was also aware that symptoms of chronic diarrhoea and discomfort may be a type IV hypersensitivity reaction to cow's milk protein, which is reported to be associated with gastro-oesophageal reflux. In view of the persistence of symptoms there were some concerns regarding compliance, but it was decided to await events.

Grant was admitted to hospital at 8 months of age with acute gastroenteritis caused by rotavirus, from which he made a full recovery and was noted to be passing normal stools before discharge.

At 11 months of age, he was seen in clinic and his parents reported that he passed six loose stools per day with blood and mucous. He had stopped vomiting and clinical examination was unremarkable. His oesophageal pH study showed a reflux index (1.5%) (normal < 4.0%). During this study his parents pressed the event marker eight times because of "pains", but none of the events coincided with changes in oesophageal pH.

At 12 months of age he was admitted again with diarrhoea and vomiting. *Campylobacter* species was isolated from stool. He was passing normally formed stools at the time of hospital discharge.

For a period of four weeks, under close dietetic supervision (dairy- and egg-free diet), his parents reported resolution of the pain and diarrhoea. Grant continued to thrive with height and weight following the 75th and 91st centiles, respectively.

It was thought that since the stool frequency and consistency were normalising on the dairy and egg exclusion diet, the suspicion of a dairy and/or egg intolerance was confirmed. No further investigations were organised and a later introduction of dairy products was planned.

Grant returned to the clinic at 15 months of age with a history of severe diarrhoea, perineal excoriation, and weight loss. Physical examination was normal, no perineal excoriation was present, and his weight remained on the 91st centile (11.5 kg). Investigations were normal (table 1). Grant was continued on a strict dairy-free diet, with Neocate.

COMMENT

► Perineal excoriation is an important clinical sign in chronic diarrhoea, indicating the likely presence of acidic stool that is often caused by bacterial fermentation of maldigested sugars. It is important to distinguish it from napkin dermatitis and *Candida* infection. Conditions associated with an acquired carbohydrate maldigestion generally involve the small bowel

See end of article for authors' affiliations

Correspondence to:
Dr David I Campbell, Queen Elizabeth Hospital, Sheriff Hill, Gateshead, NE9 6SX, UK; d.i.campbell@ncl.ac.uk

Table 1 Summary of investigations before referral to tertiary specialist

Investigation	Comment
Haemoglobin 11.5 g/dl (7.2 mmol/l)	Normal
White cell count $9.5 \times 10^6/l$	Normal
Platelet count $315 \times 10^6/l$	Normal (acute phase reactant in IBD)
Renal function	Normal
Liver biochemistry	Normal
C reactive protein <6 mg/dl	Normal
Prothrombin time 13 seconds	Suggests fat soluble vitamin malabsorption unlikely
Sweat chloride 20 mmol/l	Normal
IgG, IgA, IgM	Normal on 2 occasions
IgG ₁₋₄ subclasses	Normal age appropriate values
Endomesial antibodies	Normal on two occasions (once when eating gluten)
RAST to milk and egg	Negative on two occasions

IBD, inflammatory bowel disease; Ig, immunoglobulin; RAST, radioallergosorbent test.

(table 2), and are associated with increased epithelial mitotic rates and the migration of immature enterocytes onto the luminal surface. These immature enterocytes have a poorly formed glycocalyx border that lacks a full compliment of disaccharidases. Without mature disaccharidases, carbohydrates are maldigested and presented to the colon in increased quantities, where they are fermented by commensal bacteria to produce acidic byproducts.

- ▶ Normal inflammatory markers (white cell count and platelet count, C reactive protein, and immunoglobulin concentrations) indicate the absence of systemic inflammation, but can be normal even in grossly inflamed intestinal mucosa. The demonstration of mucosal inflammation requires an endoscopy and histological examination of affected tissue.
- ▶ An amino acid based formula such as Neocate is necessary to treat the complex food intolerance (including oligopeptide sensitivity), but an extensively hydrolysed formula is usually adequate.

The general paediatrician considered that despite normal blood inflammatory markers, Grant may be suffering either from inflammatory bowel disease (although very rare in children under 5 years of age), or an enteropathy. He thought that an endoscopy and histological examination of large and small bowel biopsies was necessary and so referred Grant to a paediatric gastroenterologist.

The paediatric gastroenterologist saw Grant at 17 months of age. The history was reviewed and no additional clinical features were evident. His parents again reported perineal excoriation but none was

evident on examination. His weight (12.7 kg) remained on the 91st centile. His parents were convinced that a more serious disease was causing Grant's symptoms and were keen for further investigations.

Colonoscopy and upper bowel endoscopy was performed under general anaesthetic. Small bowel macroscopic and histological examination was entirely normal. Large bowel mucosa was abnormal with diffuse ring-like red/brown lesions from the rectum through to the caecum (fig 1, left panel). Lesions were more densely sited on the right side of the large bowel, and some had a raised pale centre (fig 1, right panel). Biopsies showed numerous lymphoid follicles with no acute inflammatory changes and no melanosis coli. A 99m technetium white cell scintigram found no evidence of increased uptake anywhere in the body.

COMMENT

- ▶ Melanosis coli can be confirmed histologically by the presence of dark brown intracellular collections of pigment within macrophages. These pigments are known to be forms of lipofuscin, derived from apoptotic epithelial cells,^{1,2} which increase in number with chronic anthraquinone (that is, senna) use. Laxative abuse is not the only cause of melanosis coli and other conditions such as inflammatory bowel disease or haemosiderosis have been associated with colonic submucosal pigmentation.

The paediatric gastroenterologist was uncertain how to interpret the macroscopic findings. The presence of numerous, well formed lymphoid follicles raised the possibility of allergy or intestinal inflammation. The normal radiolabelled

Table 2 Conditions associated with acquired carbohydrate malabsorption

Condition	
Post-enteritis syndrome Rotavirus <i>Giardia lamblia</i> <i>Salmonella</i> species <i>Campylobacter</i> species	Possible after any enteric infection
Type IV hypersensitivity syndromes Coeliac disease Cow's milk sensitive enteropathy (CMSE) Autoimmune enteropathy Graft versus host disease Host versus graft (small bowel allograft rejection)	This mechanism of epithelial damage underlies the post-enteritis syndrome, which may be complicated with protein sensitisation, i.e. CMSE
Primary carbohydrate maldigestion ▶ Lactose intolerance (2 q21) ▶ Glucose-galactose malabsorption (22 q13) ▶ Sucrase-isomaltase deficiency (3q 25-26)	Milder forms of single gene defects may be unrecognised even through to adult life (more common with sucrase isomaltase and lactose intolerance)

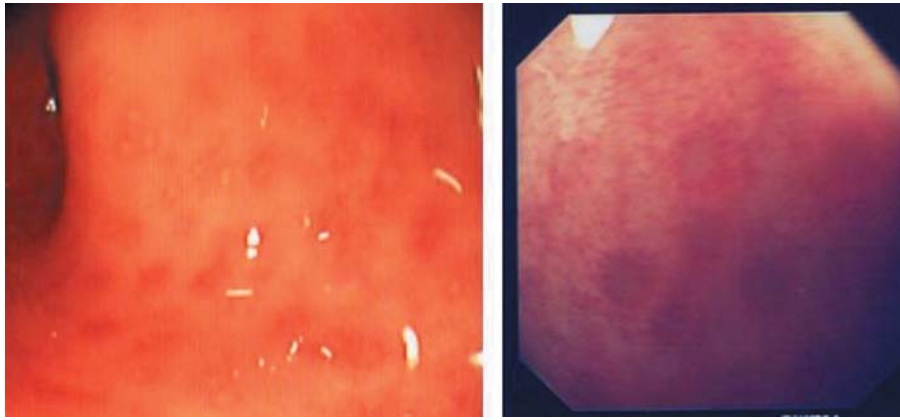


Figure 1 Appearances of large bowel mucosa at colonoscopy (close up view of pigmented lesions on right).

white cell scan suggested the observed lesions were not caused by a highly active inflammatory condition. It was therefore decided to treat presumed allergy with continuation of the restricted diet (dairy, egg, and soya exclusion) with Neocate as a milk substitute.

Grant's parents reported a continuation of the same symptoms despite the use of the restrictive diet for eight weeks. The paediatric gastroenterologist found no abnormal clinical features and the child continued to gain weight normally, yet the parents were insistent that further medical examinations and investigations should be undertaken.

The parental attitude and the discrepancy between the reported and observed clinical features led to concerns about induced or exaggerated illness. The paediatric gastroenterologist discussed the situation with colleagues and identified two choices: separate Grant from his parents (using child protection procedures) and observe, or investigate symptoms further. Continuing invasive investigations in the presence of induced (or fabricated) illness would cause distress and pain and leave Grant in a potentially abusive home environment. On the other hand, separating Grant from his parents could also be distressing to him and did not take into account the possibility of gastrointestinal disease that was suggested by the colonoscopic findings and large bowel histology.

Faecal laxative screening was undertaken (a combination of thin layer chromatography, mass spectrometry, measurement of faecal magnesium, and estimation of the faecal osmotic gap). The magnesium concentration of liquid stool was 135 mmol/kg (normal < 20 mmol/kg), and the faecal osmotic gap was 140 mosmol/kg (normal < 100 mosmol/kg), leading to concerns that Grant was either being poisoned, or that he had a genuine intestinal magnesium losing state. No other laxatives were detected in the stool.

COMMENT

▶ A raised faecal osmotic gap indicates osmotic diarrhoea, which is usually caused by unmeasured organic anions (non-electrolytes). In secretory diarrhoea, where there is usually a defective electrolyte transporter, allowing efflux of electrolytes, the concentration of sodium is usually higher (that is, > 75 mmol/l rather than < 20 mmol/l, as seen in osmotic diarrhoea) and the osmotic gap is usually less than 100 mosmol/kg. Stool that has water added to it has a low electrolyte concentration and low osmolality (< 200 mosmol/kg).

- ▶ Despite the apparent osmotic nature of the faecal biochemistry we could not be sure this child did not have a Mg^{2+} malabsorption. Even though he was never hypomagnesaemic, it was not possible to explain away his abnormal colonoscopic findings satisfactorily. The possibility of induced or organic disease therefore remained.
- ▶ Extremely rare single gene defects in intestinal magnesium channels have been described³⁻⁵ and are usually associated with hypomagnesaemia. Other gastrointestinal disorders (particularly pancreatic disease) can lead to the loss of large amounts of magnesium because of malabsorption, but it also accompanies steatorrhoea from any cause since magnesium absorption is inhibited by chelation with fatty acids.

The clinical scenario created a dilemma. Although the clinical picture presented by Grant did not fit the features of congenital magnesium losing diarrhoea, the abnormal macroscopic findings at colonoscopy and the high concentrations of faecal magnesium meant that the possibility of organic disease could not be dismissed. But neither could the possibility of induced or fabricated illness. It was decided to hold a multidisciplinary (paediatric gastroenterologist, paediatric nephrologist, a child protection specialist, dietician, pharmacist, and a senior nurse) strategy meeting. It was decided to arrange hospital admission promptly to perform further investigations to assess magnesium balance to demonstrate whether Grant was losing magnesium via the gut, due to an intrinsic disease or because of excess magnesium administration.

COMMENT

▶ Magnesium is the fourth most abundant body mineral, the majority of which is stored intracellularly or within the skeleton. Factors altering intestinal uptake are not well understood but involve a variety of specific divalent cation active channels.⁶ Intestinal absorptive fractions of dietary magnesium vary from 30–60% depending on whether body stores are replete or depleted.⁷ The main regulator of magnesium stores is the nephron, with the thick limb of the ascending loop of Henley controlling the proportion excreted or reabsorbed. Parathormone (PTH) sensitive magnesium channels control the reabsorption of filtered magnesium from the nephron. Depleted magnesium stores result in normo- or hypomagnesaemia with raised PTH, a low fractional urinary excretion of magnesium, and hypocalcaemia if the PTH concentration is raised (fig 2). The PTH response to hypocalcaemia is blunted by hypomagnesaemia,⁸ but in normocalcaemia the response to chronic hypomagnesaemia is an increase in PTH

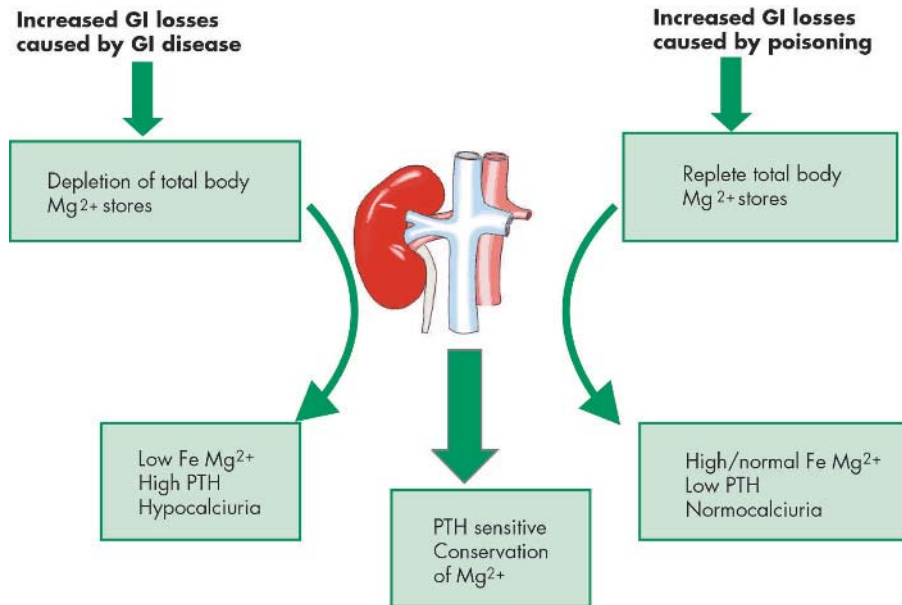


Figure 2 Measurable physiological responses to magnesium loss caused by poisoning and organic intestinal disease. GI, gastrointestinal; PTH, parathormone.

ep71

concentrations to reduce renal magnesium loss. In contrast, excess total body magnesium stores result in normal or raised fractional urinary excretion of magnesium, normal or low PTH, and no hypocalciuria.

- ▶ Diarrhoea caused by magnesium secreting gastrointestinal disease is associated with depleted total body magnesium stores, whereas diarrhoea caused by poisoning is associated with excess total body magnesium. Renal biochemistry and PTH concentrations are critical in assessing total body magnesium and will differentiate between excess and depleted magnesium states. Furthermore, magnesium secreting diarrhoea and other magnesium losing states will be sensitive to total body magnesium stores. Replenishing magnesium stores should result in an increase in faecal magnesium output, which can be observed as the response to intravenous loading with magnesium.

Consideration was given to the possibility of an unintentional excess of magnesium in the diet, but this was thought to be unlikely. Similarly, an innocent parental administration of magnesium containing drugs was considered to be relatively implausible. Senior nursing colleagues were therefore alerted to the possibility of poisoning, so Grant was given a bed on an open ward next to the nurses' desk where he could be observed. Particular care was taken in the recording of specimen collections and documenting the sites of cannulae and venepunctures.

Details of investigations, their indications, and results are summarised in table 3. A dietary and drug review (by a paediatric dietician and a paediatric pharmacist) revealed no excess magnesium intake. Grant's parents claimed that while he was receiving Neocate, he drank 3 litres per day and yet the prescription database of the GP (the sole supplier) indicated that less than 2 litres per day was prescribed. Plasma magnesium was normal. Fractional urinary excretion of magnesium was normal. Faecal magnesium concentration was interpreted as slightly raised although the normal range is not well established. The PTH concentration was slightly low. A chest x ray showed no evidence of metabolic bone disease. Faecal microscopy and culture excluded steatorrhoea, infection, and parasitic infestation.

The slightly low PTH concentration, the absence of radiological evidence of metabolic bone disease, the normal plasma magnesium concentration, and the high faecal magnesium concentration were interpreted as evidence of mild magnesium loss from the bowel with adequate body magnesium stores.

Intravenous magnesium loading (3 mmol magnesium sulphate over six hours) increased plasma

Table 3 Investigations to differentiate gastrointestinal magnesium losing states and excessive enteral administration

Investigation	Reason for investigation	Final result
Dietetic history	Potential innocent explanation for high Mg ²⁺ input	High intake of Neocate factitious, prescriptions never collected
Pharmacological history	Inadvertent ingestion of magnesium or calcium containing drugs	No magnesium or calcium containing drugs taken
Faecal magnesium concentration	Confirm chronic loss	Figure 3
PTH concentration	Assess body stores	17 ng/ml (low normal)
Fractional urinary magnesium excretion*	Assess body stores	3.36% (normal <4%)
Renal function	Assess body stores	Normal
Chest x ray	Evidence of secondary hyperparathyroidism	Normal
Intravenous challenge with magnesium	To detect increased intestinal magnesium loss if inborn error of intestinal magnesium handling	Figure 3
Washout period	To enable concentrations to fall to baseline	Figure 3
Oral magnesium challenge	To replicate baseline findings	Figure 3

*Urinary fractional excretion of magnesium = $[\text{Ur Mg}^{2+}]/[\text{Pl Mg}] \times [\text{Pl Mg}]/[\text{Ur Mg}^{2+}]$.

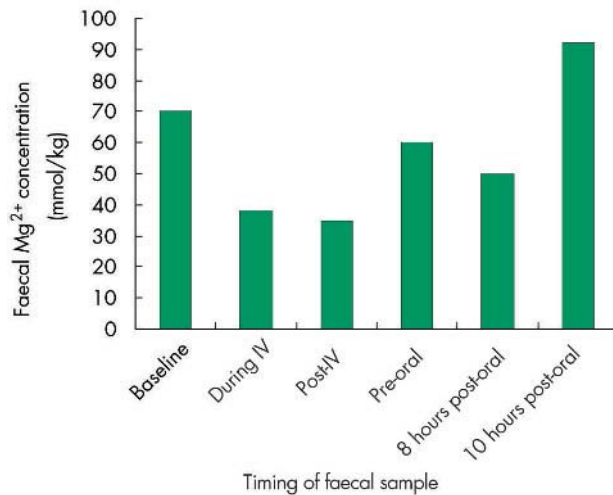


Figure 3 Faecal magnesium concentrations before and during intravenous (IV) and oral magnesium challenges.

magnesium to 1.6 mmol/l (fig 3). Fractional urinary excretion of magnesium rose to 5.3% (an appropriate response to hypermagnesaemia) and then returned to baseline. Faecal magnesium concentrations fell towards normal values during the intravenous infusion. Stools continued to be loose throughout this time.

COMMENT

▶ A rise in plasma magnesium concentration together with a corresponding rise in urinary fractional excretion of magnesium is strong evidence that the body stores of magnesium are replete. In a state of magnesium depletion caused by secretory diarrhoea, an intravenous loading dose of magnesium will result in an increase in faecal magnesium loss. The observed fall in faecal magnesium concentration was evidence against this and does not rely on interpretation of individual stool magnesium concentrations which are easily criticised because of a lack of normal ranges below the values seen in magnesium poisoning.

Oral loading resulted in faecal magnesium concentrations rising to 90 mmol/kg within 10 hours. This replicated the magnesium concentrations (100–135 mmol/kg) that were seen while Grant was at home. Nursing observations confirmed 3–4 loose stools per day and a good appetite while he was eating a normal diet. Apart from when he was on the intravenous infusion, he played and had frequent trips off the ward, which were unsupervised. No suspicious events were observed during his hospital stay.

It was concluded that Grant had no evidence of total body magnesium depletion and no evidence of a magnesium secreting diarrhoea or intestinal magnesium losing state. Replication of previously high faecal magnesium values was seen with oral dosing. Since the balance of evidence was against an organic magnesium losing state, his parents were persuaded to allow Grant to be admitted to his local hospital for two weeks.

In hospital, Grant had restricted ward leave and had closely supervised parental visiting (via a nurse

chaperone). He passed formed stools once per day, no pain was observed, and he ate a normal diet. Child protection procedures were invoked and Grant and his older sibling were taken into local authority care. In an interview, Grant's father confessed to tampering with samples during the hospital stay by adding water to the stool (this was not detected because sequential stool osmolality was not performed on the inpatient samples). A police search of the family home found a supply of several different laxatives, but none contained magnesium. Significant amounts of Gaviscon (237 mg of magnesium carbonate per 5 ml dose) were found.

In our experience, it is not uncommon for a differential diagnosis to include both rare medical conditions and factitious or induced illness. In this case, Grant presented with a potentially rare disease (only 30 cases of intestinal magnesium malabsorption/secretory diarrhoea have been reported worldwide).^{5–10} The common approach adopted by paediatricians is to admit the child with supervised parental visiting and repeat investigations and nursing observations to see if symptoms disappear. This approach can result in significant interference with family life and antagonism towards hospital staff.¹¹ If parents are not compliant, then further action may be needed to enforce the admission. An approach that embarks upon restricting parental access to their child, without having first obtained firm evidence of possible induced illness, may not be in the child's best interest.

COMMENT

▶ Magnesium poisoning has long been recognised as a condition that produces symptoms that will fully engage medical attention and is readily available over the counter in the form of Epsom salts¹² and alginate antacids such as Gaviscon. The gold standard investigation for assessing total body magnesium stores utilises stable isotope dilution techniques,¹³ but these are only available as research tools. Normal values for fractional urinary excretion of magnesium have been defined in both health and disease,¹⁴ particularly in renal magnesium losing states such as Gittelmann's syndrome. Although the renal magnesium sensing capacity is well documented and quantified, the molecular mechanism by which it does this, and how PTH concentrations respond to changes in total body magnesium stores, is not well understood. Normal ranges and fractional urinary excretion of magnesium enable the indirect estimation of total body magnesium stores, allowing the clinician to differentiate between intestinal magnesium loss caused by excess magnesium intake and that caused by intestinal pathology.¹⁵ This procedure, following an intravenous magnesium challenge, has also been proposed to detect magnesium depletion in chronic pancreatitis.¹⁶ Yet, intravenous magnesium infusion is potentially hazardous, and should only be used if the diagnosis cannot be otherwise confirmed. Potentially a normal baseline urinary fractional excretion of magnesium would demonstrate no depletion of magnesium body stores, and would enable an intravenous load of magnesium to be avoided. However, an intravenous magnesium load followed by a high fractional urinary excretion of magnesium shows with greater certainty body stores of magnesium are replete, and enables the faecal magnesium concentrations to show no magnesium secreting diarrhoea. The lead clinicians need to decide, on a case by case basis, whether or not such information is necessary.

- ▶ We would add a further word of caution when dealing with unusual physiological tests such as faecal chemistry. Doubts about age appropriate normal ranges should encourage a wider physiological approach, such as dynamic tests and the inclusion of other organs (that may share the same aberrant ion channels)—that is, renal biochemistry.
- ▶ Adopting a physiological approach to potential poisoning may enable child protection procedures to proceed with greater confidence, and encourage an appropriate balance between excess caution and overdiagnosis. It has been stated in this journal that “in order to give the best care to patients and families, paediatricians need to integrate the highest quality of scientific evidence with clinical expertise”.¹⁷ We would support such demands within the realms of child protection, but determining the exact timing of when medical investigations should stop and child protection proceedings should start can only be decided on a case by case basis and in the context of a multidisciplinary team.

For further information readers are referred to the guidelines for the investigation of chronic diarrhoea¹⁸ and the Royal College of Paediatrics and Child Health working party report on investigation of fabricated or induced illness in carers.¹⁹

ACKNOWLEDGEMENTS

Dr Andy Duncan, Department of Biochemistry, Glasgow Royal Infirmary, medical and nursing staff at The Royal Victoria Infirmary, Newcastle-upon-Tyne.

.....

Authors' affiliations

D I Campbell, J Clarke, S Watson, S Court, Department of Paediatrics, Royal Victoria Infirmary, Newcastle-upon-Tyne, UK

M Ognjanovic, Department of Paediatric Nephrology, Royal Victoria Infirmary, Newcastle-upon-Tyne, UK

H L Smith, Department of Paediatrics, Bishop Auckland Hospital, County Durham, UK

This case is based on experience from several cases. Details have been altered to ensure patient anonymity.

Competing interest: None real or perceived

REFERENCES

- 1 **Ghadially FN**, Walley VM. Melanoses of the gastrointestinal tract. *Histopathology* 1994;**25**:197–207.
- 2 **Byers RJ**, Marsh P, Parkinson D, *et al*. Melanosis coli is associated with an increase in colonic epithelial apoptosis and not with laxative use. *Histopathology* 1997;**30**:160–4.
- 3 **Nadler MJS**, Hermosura MC, Inabe K, *et al*. LTRPC7 is a Mg-ATP-regulated divalent cation channel required for cell viability. *Nature* 2001;**411**:590–5.
- 4 **Walder RY**, Shalev H, Brennan TMH, *et al*. Familial hypomagnesemia maps to chromosome 9q, not to the X chromosome: genetic linkage mapping and analysis of a balanced translocation breakpoint. *Human Molecular Genetics* 1997;**6**:1491–7.
- 5 **Skyberg D**, Stromme JH, Nesbakken R, *et al*. Neonatal hypomagnesaemia with selective malabsorption of magnesium – a clinical entity. *Scand J Clin Lab Invest* 1968;**21**:355–63.
- 6 **Bijvelds MJ**, Flik G, Kolar ZI. Cellular magnesium transport in the vertebrate intestine. *Magnesium Research* 1998;**11**:315–22.
- 7 **Schweigel M**, Martens H. Magnesium transport in the gastrointestinal tract. *Frontiers in Bioscience* 2000;**5**:D666–77.
- 8 **Allgrove J**, Adami S, Fraher L, *et al*. Hypomagnesaemia: studies of parathyroid hormone secretion and function. *Clin Endocrinol* 1984;**21**:435–9.
- 9 **Romero R**, Meacham LR, Winn KT. Isolated magnesium malabsorption in a 10-year old boy. *Am J Gastroenterol* 1996;**91**:611–3.
- 10 **Jin-no Y**, Kamiya Y, Okada M, *et al*. Primary hypomagnesemia caused by isolated magnesium malabsorption: atypical case in adults. *Internal Medicine* 1999;**38**:261–5.
- 11 **Pragnell C**. Fabricated or induced illness in children: open mind is needed regarding origins of childhood symptoms and illnesses. *BMJ* 2002;**324**:114–5.
- 12 **Fenton AC**, Wailoo MP, Tanner MS. Severe failure to thrive and diarrhoea caused by laxative abuse. *Arch Dis Child* 1988;**63**:978–9.
- 13 **Abrams SA**, Wen JP. Methodologies for using stable isotopes to assess magnesium absorption and secretion in children. *J Am Coll Nutrition* 1999;**18**:30–5.
- 14 **Quamme GA**. Renal magnesium handling: new insights in understanding old problems. *Kidney International* 1997;**52**:1180–95.
- 15 **Fine KD**, Santa Ana CA, Fordtran JS. Diagnosis of magnesium-induced diarrhea. *N Engl J Med* 1991;**324**:1012–17.
- 16 **Papazachariou IM**, Martinez-Isla A, Efthimiou E, *et al*. Magnesium deficiency in patients with chronic pancreatitis identified by an intravenous loading test. *Clin Chim Acta* 2000;**302**:145–54.
- 17 **Phillips B**. Towards evidence based medicine for paediatricians. *Arch Dis Child* 2003;**88**:1131.
- 18 **Thomas PD**, Forbes A, Green J, *et al*, eds. Guidelines for the investigation of chronic diarrhoea. *Gut* 2003;**52**(suppl V):v1–15.
- 19 **Royal College of Paediatrics and Child Health**. Fabricated or induced illness in carers. Report of the working party of the Royal College of Paediatrics and Child Health. London: RCPCH, 2002; 1–74, http://www.rcpch.ac.uk/publications/recent_publications/FII.pdf.

CROSSWORD.....

Answers

ACROSS

- 2) Language line, 4) Cardiomyopathy, 5) Amoxicillin, 6) Cataract, 7) Metformin, 12) Homozygous, 13) Ribavirin, 17) Methotrexate, 21) Agonist, 27) Quotidian, 28) Lifestyle change, 29) Remodelling

DOWN

- 1) Buccal scrape, 3) Leydig, 6) Chloride, 8) Reiter, 9) Roux-en-Y, 10) Hypothyroidism, 11) Cushing, 14) Prostacyclin, 15) DNase, 16) Prothrombin, 18) Fractionation, 19) Steatorrhoea, 20) Seventeen, 22) Advocate, 23) Colistin, 24) Koebner, 25) Benzene, 26) Placebo