

On the edge of the film...

Helen Williams



INTRODUCTION

Review areas: in radiology these are areas on a radiograph where pathology can be easily overlooked. The term is usually applied to the chest radiograph (CXR) where review areas include behind the heart (left lower lobe), under the diaphragms, lung apices, bones and soft tissues and around the edge of the image. When interpreting the CXR, it is helpful to check these areas systematically so that potentially important abnormalities are not missed. Answers to the following two quiz questions can be found on page 40.

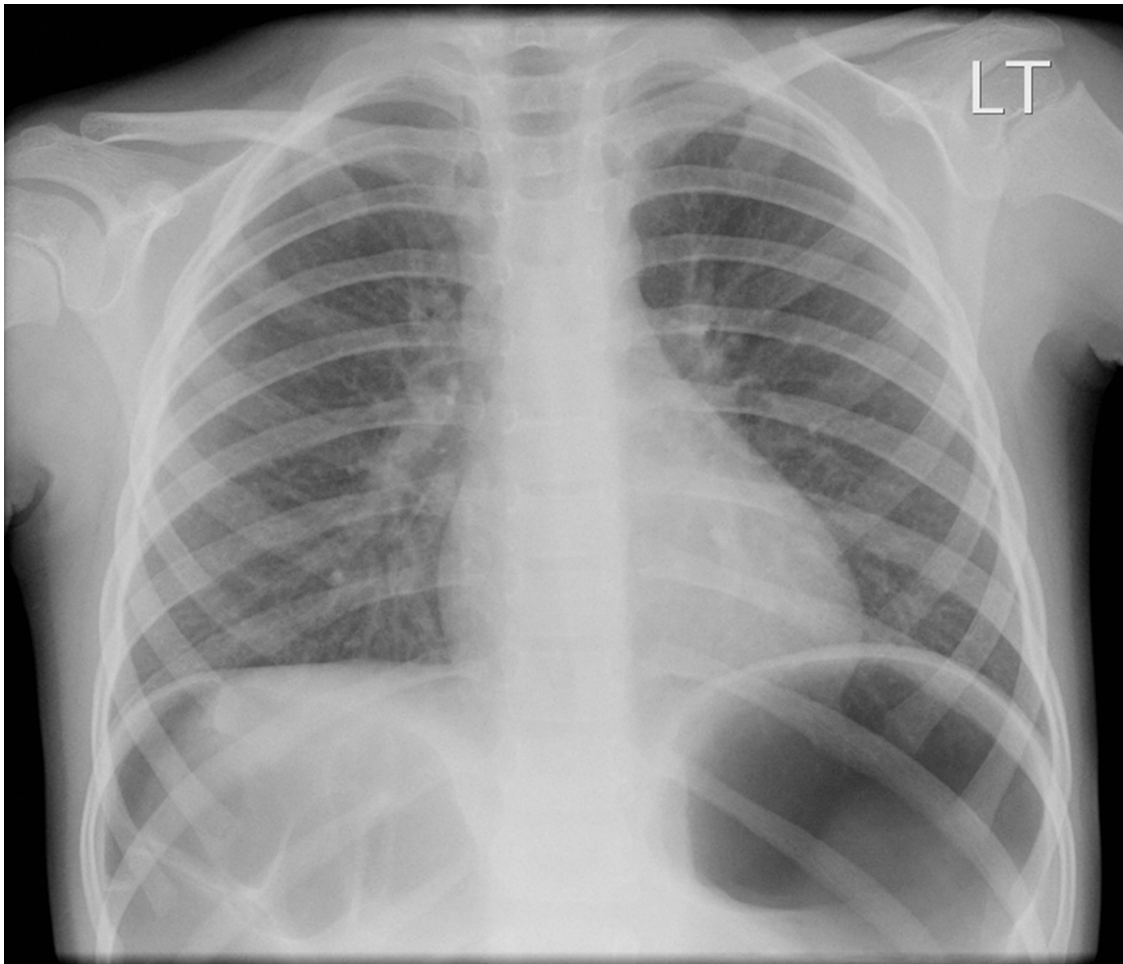


Figure 1

QUESTION 1

A 5-year-old girl was referred for CXR (figure 1) by her general practitioner because she had a persistent cough for 9 weeks. What is the diagnosis? Is this a significant finding?

Question 1 Select one option from the following:

- A. Morgagni hernia
- B. Intramural gas
- C. Spigelian hernia
- D. Diaphragmatic eventration
- E. Chilaiditi's sign
- F. Free intraperitoneal gas
- G. Abdominal situs inversus
- H. Bochdalek hernia

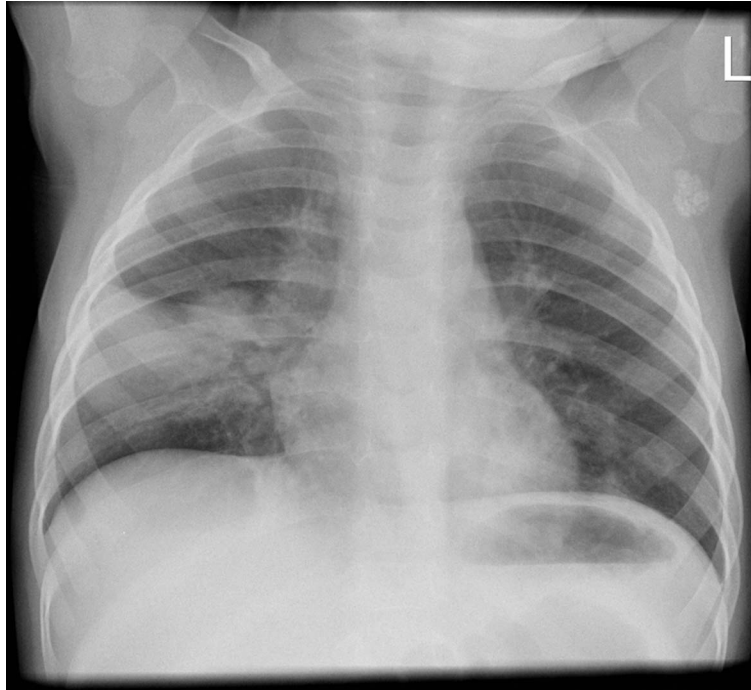

Figure 2

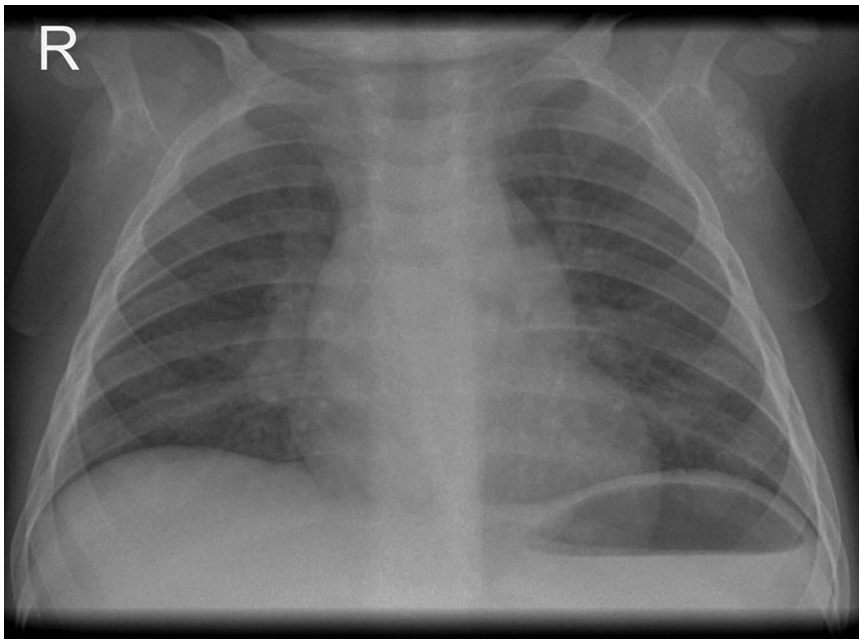


Figure 3

QUESTION 2

A 10-month-old boy presented with respiratory distress, hypoxia and pyrexia. His initial CXR is shown in figure 2. He responded well to amoxicillin and was discharged after 4 days. A repeat CXR (figure 3) was obtained at clinical follow-up. What is the likely explanation for the persistent extrapulmonary abnormality on his CXR?

Question 2 Select one option from the following:

- A. Atypical mycobacterial infection
- B. *Mycoplasma pneumoniae*
- C. Metastatic malignancy
- D. Tuberculosis
- E. Lymphadenitis
- F. Previous BCG vaccination
- G. Neuroblastoma
- H. Cat scratch disease