



# Importance and impact of diversity in paediatric medical education

Dhurgshaarna Shanmugavadivel <sup>1</sup>, Danilo Buonsenso <sup>2</sup>,  
Kaylita Chantiluke,<sup>3</sup> Michelle Arora <sup>4</sup>

<sup>1</sup>Children's Brain Tumour Research Centre, Nottingham Children's Hospital, Nottingham, UK

<sup>2</sup>Department of Woman and Child Health and Public Health, Fondazione Policlinico Universitario A. Gemelli IRCCS, Rome, Italy

<sup>3</sup>Department of Paediatric Emergency Medicine, Sunshine Hospital, Saint Albans, Victoria, Australia

<sup>4</sup>Department of Paediatrics, University of Cambridge, Cambridge, UK

## Correspondence to

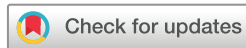Dr Michelle Arora, Department of Paediatrics, University of Cambridge, Cambridge CB2 0QQ, UK; ma804@medschl.cam.ac.uk

Received 25 November 2020

Accepted 26 July 2021

Published Online First

6 September 2021



© Author(s) (or their employer(s)) 2022. Re-use permitted under CC BY-NC. No commercial re-use. See rights and permissions. Published by BMJ.

**To cite:** Shanmugavadivel D, Buonsenso D, Chantiluke K, et al. *Arch Dis Child Educ Pract Ed* 2022;**107**:455–457.

## ABSTRACT

Despite the increasing diversity of the UK population, we continue to see inequalities in health outcomes in patients of ethnic minorities. Unfortunately, this increasing diversity is not reflected in educational resources, which often continue to feature few images of patients with darker skin tones. Given the lack of diversity in these resources, it is unsurprising that healthcare professionals find it challenging recognising, diagnosing and managing presentations of clinical conditions in darker skinned patients. The development of new online, accessible image banks of medical conditions in different skin tones, such as Skin Deep, aims to facilitate increasing diversity in educational materials and hence improve delivery of equal standards of care to all patients.

## INTRODUCTION

In the era of Black Lives Matter, equality, diversity and inclusion are high on the public and healthcare agenda. Due to increasing emigration and globalisation, the cultural landscape of the world is rapidly changing, leading to a significant increase in ethnic diversity in our population and bringing with it a variety of clinical presentations, health conditions and beliefs. Unfortunately, identifying as a member of an ethnically minoritised group is a well-known determinant of poor health status<sup>1–3</sup> and to ensure that all patients receive equitable healthcare, establishing educational practices and health systems that reflect our multicultural society is essential.

## A PICTURE PAINTS A THOUSAND WORDS

Medical images are an invaluable resource to facilitate recognition of clinical signs. Unfortunately, the increasing diversity of the population is not reflected in current educational resources. Recent studies highlight an implicit racial bias due to a lack of skin tone representation within teaching materials, including textbooks, online resources,

lecture slide decks and case studies.<sup>4–7</sup> Key medical textbooks also lack skin tone diversity, with 74.5% of over 4000 images being of light skin tones at textbook, chapter and topic level,<sup>4</sup> and a further study reviewing 747 Powerpoint slide decks at one American medical school found that of 5023 images, 78.4% were light and 21.6% were darker skin tones.<sup>5</sup> Furthermore, a review of 1381 images published in the *New England Journal of Medicine* from 1992 to 2007 found only 18% of images depicted presentations in darker skin.<sup>6</sup> This lack of diversity highlights an urgent need for a cultural shift.

## DIVERSITY IN MEDICAL EDUCATION OF DERMATOLOGICAL CONDITIONS

An area where this is particularly pertinent is dermatology. This is evidenced by the fact that an educational resource by the British Association of Dermatology, which aimed to improve recognition of the dermatological manifestations of COVID-19, was subject to criticism due to a lack of skin tone diversity<sup>8 9</sup>; a survey of Australian dermatologists found that 80% of responders desired more specific skin tone teaching<sup>10</sup>; and a study of American dermatology training programmes found that only 25.4% had lectures on 'skin of colour' and only 30.2% gained experience in treating patients with darker skin tones.<sup>11</sup>

Within paediatrics, the diagnosis of many dermatological and genetic conditions relies on the recognition of characteristic features, which can present differently depending on skin tone and ethnicity. Descriptions of rashes frequently focus on redness or pallor, both of which are harder to recognise in darker skin tones or may not be present at all, potentially resulting in a missed or late diagnosis.

## THE IMPACT ON CLINICAL PRACTICE

Despite significant evidence of the lack of diversity in medical education, there is a surprising paucity of data on the effect this may have on patient care. For example,



**Figure 1** A child with jaundice.

cyanosis (<https://dftbskindeep.com/all-diagnoses/central-cyanosis>) is a key clinical sign in a number of paediatric disorders and is classically described as a blue-purple hue. However, in children with darker skin tones, it may appear as grey or white and at present there are no studies examining how this may affect patient outcomes.<sup>12</sup>

Another important example is the ability to recognise a meningococcal septicaemia rash (<https://dftbskindeep.com/all-diagnoses/meningococcal-septicaemia/>) in darker skin tones. Resources developed by the Centers for Disease Control and Prevention show a total of 13 images of this rash, all of which are in children with light skin tones.<sup>13 14</sup> The 2018 UK edition of the 'Meningococcal Meningitis and Sepsis Guidance Notes—Diagnosis and Treatment in General Practice' provides seven images of skin manifestations in meningococcal septicaemia with only two of them in children with darker skin tones, despite this disease having a higher mortality in ethnically minoritised groups with darker skin tones.<sup>15 16</sup> Although the reasons for increased mortality in these populations are multifactorial, delayed recognition of the dermatological signs of this disease cannot be excluded.

Neonatal jaundice (figure 1) is a common yet potentially life-threatening condition which is more easily identifiable in infants with lighter skin tones. Infants from particular ethnicities are at a higher risk of jaundice due to the increased prevalence of certain haemolytic anaemias such as glucose-6-phosphate dehydrogenase deficiency. The detrimental effects of this, and the marked health-care inequalities present in the USA, contribute to black infants being at significantly increased risk of hyperbilirubinaemia, accounting for more than 25% of kernicterus cases in the USA.<sup>17</sup>

Pallor (figures 2 and 3) is a principal clinical sign in diagnosing anaemia, and the Integrated Management of Childhood Illness guidelines developed by the WHO and UNICEF recommend examining for palmar and conjunctival pallor to identify anaemia.<sup>18</sup> However, a WHO study showed that pallor of the conjunctiva, tongue, palm



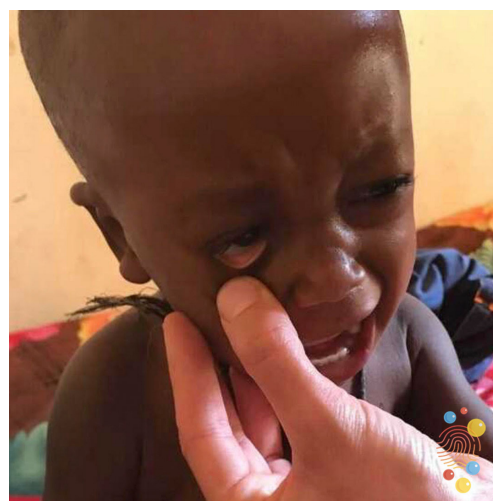
**Figure 2** A child with palmar pallor.

or nail bed was 66% sensitive and 68% specific in recognising moderate anaemia and 93% sensitive and 57% specific in recognising severe anaemia.<sup>19</sup> Furthermore, palmar pigments may vary; a study by Ughasoro *et al* found that the ability to recognise pallor in children with darker skin varied according to the skin tone.<sup>20</sup>

These examples highlight how recognising clinical signs in children with darker skin tones may contribute to challenges with diagnosis, as well as the desperate need for research into the effect this may have on health outcomes. Therefore, it is imperative that clinicians actively address this research question and seek out diverse educational resources.

#### DEVELOPMENT OF DIVERSE RESOURCES

Developing diversity in medical educational resources is hindered by a lack of availability of relevant images. Medical student Malone Mukende has raised the profile of this issue into the international public domain with his project 'Mind the Gap' which is a handbook collating darker skin tone images and is complemented by the



**Figure 3** A child with conjunctival pallor.

'Brown Skin Matters' project, an online collection of diverse dermatological images.

A paediatric-specific image bank known as Skin Deep is a global collaboration launched by the international paediatric medical education team, Don't Forget the Bubbles. It provides free, open-access, images of medical conditions in a range of skin tones with the aim of improving recognition of conditions in all skin tones, reducing inequalities and improving patient care by allowing all children to receive a timely and correct diagnosis. Through recent collaborations with textbook authors, Skin Deep also hopes to improve accessibility to diverse images in countries with limited availability of online resources.

## CONCLUSION

There has been global recognition of the importance of increasing the diversity of medical education resources to enable professionals to provide the best standard of care to patients, irrespective of the colour of their skin. The development of free, online image banks, such as Skin Deep, helps overcome some of the barriers to accessing diverse images. However, further collaborative work is urgently needed to target health professionals in countries with reduced access to online resources. It is important that clinicians, educators, researchers and authors evaluate their own practice, and promote equality with fully representative academic and educational resources. Avoiding and removing implicit and explicit racial biases and stereotyping is an essential part of overcoming health inequalities and in our opinion, is long overdue.

**Twitter** Dhurgshaarna Shanmugavadivel @HeadSmartFellow and Kaylita Chantiluke @MusingsMedic

**Acknowledgements** This article is written on behalf of the Skin Deep Core Team: Tessa Davis, Damian Roland, Nikki Abela, Michelle Alisio, Safeena Afzal, Oke Obiuewubi, Nikita Parekh, Alyah Seif, Keir Shiels, Aarani Somaskanthan, Holly Wakefield, Rebecca Platt. We are grateful to all members from all over the world contributing to the growing community of the Skin Deep project.

**Funding** The authors have not declared a specific grant for this research from any funding agency in the public, commercial or not-for-profit sectors.

**Competing interests** None declared.

**Patient consent for publication** Not required.

**Provenance and peer review** Commissioned; externally peer reviewed.

**Open access** This is an open access article distributed in accordance with the Creative Commons Attribution Non Commercial (CC BY-NC 4.0) license, which permits others to distribute, remix, adapt, build upon this work non-commercially, and license their derivative works on different terms, provided the original work is properly cited, appropriate credit is given, any changes made indicated, and the use is non-commercial. See: <http://creativecommons.org/licenses/by-nc/4.0/>.

## ORCID iDs

Dhurgshaarna Shanmugavadivel <http://orcid.org/0000-0002-1912-4543>  
Danilo Buonsenso <http://orcid.org/0000-0001-8567-2639>  
Michelle Arora <http://orcid.org/0000-0002-9095-454X>

## REFERENCES

- Pinder RJ, Ferguson J, Møller H. Minority ethnicity patient satisfaction and experience: results of the National cancer patient experience survey in England. *BMJ Open* 2016;6:e011938.
- Kai J, Beavan J, Faull C, *et al.* Professional uncertainty and disempowerment responding to ethnic diversity in health care: a qualitative study. *PLoS Med* 2007;4:e323.
- Psarros A. Mothers' voices: exploring experiences of maternity and health in low income women and children from diverse ethnic backgrounds. *Maternity Action* 2018.
- Louie P, Wilkes R. Representations of race and skin tone in medical textbook imagery. *Soc Sci Med* 2018;202:38–42.
- Martin GC, Kirgis J, Sid E, *et al.* Equitable imagery in the preclinical medical school curriculum: findings from one medical school. *Acad Med* 2016;91:1002–6.
- Massie JP, Cho DY, Kneib CJ, *et al.* A picture of modern medicine: race and visual representation in medical literature. *J Natl Med Assoc* 2021;113:88–94.
- Foronda C, Prather SL, Baptiste D, *et al.* Underrepresentation of racial diversity in simulation: an international study. *Nurs Educ Perspect* 2020;41:152–6.
- Covid-19 skin patterns. created by the British association of dermatologists. Available: [www.covidskinsigns.com](http://www.covidskinsigns.com)
- Response to guardian article on skin diversity on [www.covidskinsigns.com](http://www.covidskinsigns.com), 2020. Available: <https://www.bad.org.uk/media/news> [Accessed 25 Nov 2020].
- Rodrigues MA, Ross AL, Gilmore S, *et al.* Australian dermatologists' perspective on skin of colour: results of a national survey. *Australas J Dermatol* 2018;59:e23–30.
- Nijhawan RI, Jacob SE, Woolery-Lloyd H. Skin of color education in dermatology residency programs: does residency training reflect the changing demographics of the United States? *J Am Acad Dermatol* 2008;59:615–8.
- Sommers M. Color awareness: a must for patient assessment. American nurse. Available: <https://mvec.mcri.edu.au/immunisation-references/identifying-aefi-in-diverse-skin-colour/> [Accessed 11 Jan 2011].
- Meningococcal photos. Available: <https://www.cdc.gov/meningococcal/about/photos.html> [Accessed 08 Jan 2021].
- Meningococcal lesions on the back. Available: <https://medlineplus.gov/ency/imagepages/2938.htm> [Accessed 08 Jan 2021].
- Available: <https://vaccineinformation.org/meningococcal/photos.asp>; [Accessed 08 Jan 2021].
- Sharip A, Sorvillo F, Redelings MD, *et al.* Population-based analysis of meningococcal disease mortality in the United States: 1990-2002. *Pediatr Infect Dis J* 2006;25:191–4.
- Wickremasinghe AC, Kuzniewicz MW, Newman TB. Black race is not protective against hazardous bilirubin levels. *J Pediatr* 2013;162:1068–9.
- How to adapt the model IMCI Handbook. Available: <https://apps.who.int/iris/bitstream/handle/10665/42939/9241546441.pdf;jsessionid=4BCB260A0DA67850CA0CF302F36FC716?sequence=1> [Accessed 08 Jan 2021].
- Luby SP, Kazembe PN, Redd SC, *et al.* Using clinical signs to diagnose anaemia in African children. *Bull World Health Organ* 1995;73:477–82.
- Ughasoro MD, Madu AJ, Kela-Eke IC. Clinical anaemia detection in children of varied skin Complexion: a community-based study in Southeast, Nigeria. *J Trop Pediatr* 2017;63:23–9.