

Fifteen-minute consultation: Apparent vaginal bleeding in the pre-pubertal girl

Julie-Ann Collins,¹ Julie-Ann Maney,¹ Alison Livingstone^{2,3}

¹Emergency Department,
Royal Belfast Hospital for Sick
Children, Belfast, UK
²Community Paediatrics,
Northern Health and Social Care
Trust, Antrim, UK
³The Rowan SARC, Antrim Area
Hospital, Antrim, UK

Correspondence to

Dr Julie-Ann Collins, Emergency
Department, Royal Belfast
Hospital for Sick Children,
Belfast BT12 6BE, UK;
ja.collins@doctors.org.uk

Received 5 August 2019

Revised 23 April 2020

Accepted 3 July 2020

ABSTRACT

A parent or carer's observation of blood in a child's nappy or underwear can be quite alarming for both parent and child and may indicate vaginal bleeding. At first glance, it may be difficult to ascertain whether the bleeding is from the skin, genital tract, urinary tract or anus. Confirmed vaginal bleeding in a pre-pubertal girl is rare but always abnormal and requires comprehensive assessment to determine the cause. Recognition of normal female pre-pubertal anatomy is essential to detect any abnormalities. Appropriate action should be taken according to findings on initial inspection of the ano-genital area. The possibility of child sexual abuse and the need for specialist paediatric sexual offences medicine examination by an FME (Forensic Medical Examiner) or specialist paediatrician should always be considered. This article offers a systematic approach to assessment in pre-pubertal girls with apparent vaginal bleeding which will benefit general paediatricians, emergency department practitioners and GPs.

INTRODUCTION

A parent or carer's observation of blood in a child's nappy or underwear can be quite alarming for both parent and child. It may be difficult to ascertain the origin of the bleeding at first glance. The source of apparent vaginal bleeding may be the internal genital tract, urinary tract or bowel. The cause of the bleeding may be injury (accidental/inflicted) or a medical condition such as an external skin condition. Vaginal bleeding needs to be distinguished from haematuria and gastrointestinal (GI) bleeding. Causes of GI bleeding to consider and exclude include anal lacerations secondary to constipation or anal sexual abuse, inflammatory bowel disease, gastroenteritis and Meckel's diverticulum/intussusception.

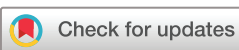Apparent vaginal bleeding in a child, who has not yet reached menarche, is a concerning presenting symptom that evokes considerable anxiety among clinicians. It is important to consider child sexual abuse (CSA) as a possible cause when a pre-pubertal girl presents either to the GP, Emergency Department or Outpatient clinic with apparent vaginal bleeding. Contact CSA affects 1 in 20 children.¹

Although an uncommon childhood presentation, vaginal bleeding pre-menarche is abnormal and must be taken seriously. It requires careful and expedient evaluation with a thorough history and examination.

WHAT CAUSES VAGINAL BLEEDING?

Non-traumatic causes of apparent vaginal bleeding in pre-pubertal girls include vulvovaginitis, infections (vaginal, urinary, sexually transmitted infections (STIs)), urethral prolapse, vaginal foreign bodies, friable posterior labial fusion (adjacent mucosal surfaces of labia minora adhere) (figure 1), hormonal causes, tumours and skin conditions such as lichen sclerosis et atrophicus (figure 2).^{2 3} While these conditions can mimic the presentation of CSA, they may also coexist with CSA. Appropriate swabs should be taken when infection suspected.²

Lichen sclerosis et atrophicus, a chronic skin condition, should be considered in girls with genital bleeding where there is a clear demarcation between normal and affected skin. The skin can be itchy and friable in the acute phase leading to subcutaneous haemorrhage and ecchymosis. Hypopigmented lesions or shiny white plaques may also be visible (figure 2). If there is doubt, a dermatological opinion±skin biopsy may be helpful.



© Author(s) (or their employer(s)) 2020. No commercial re-use. See rights and permissions. Published by BMJ.

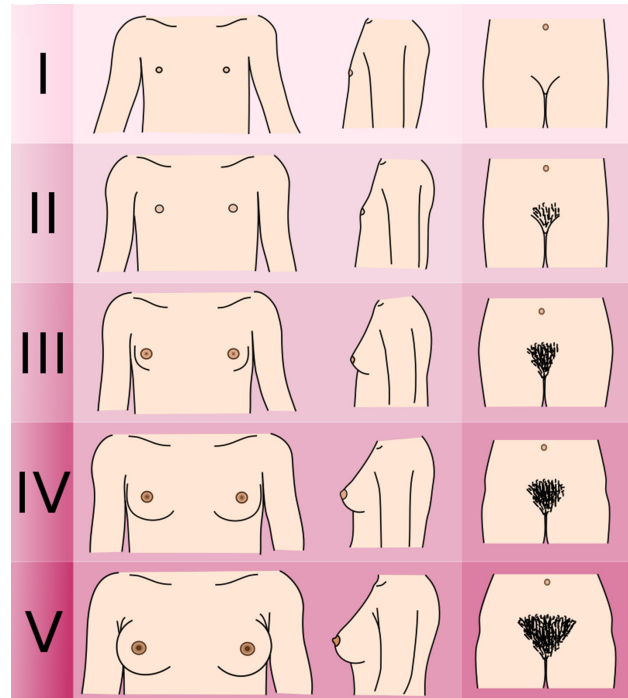
To cite: Collins J-A, Maney J-A, Livingstone A. *Arch Dis Child Educ Pract Ed* Epub ahead of print: [please include Day Month Year]. doi:10.1136/archdischild-2018-316218

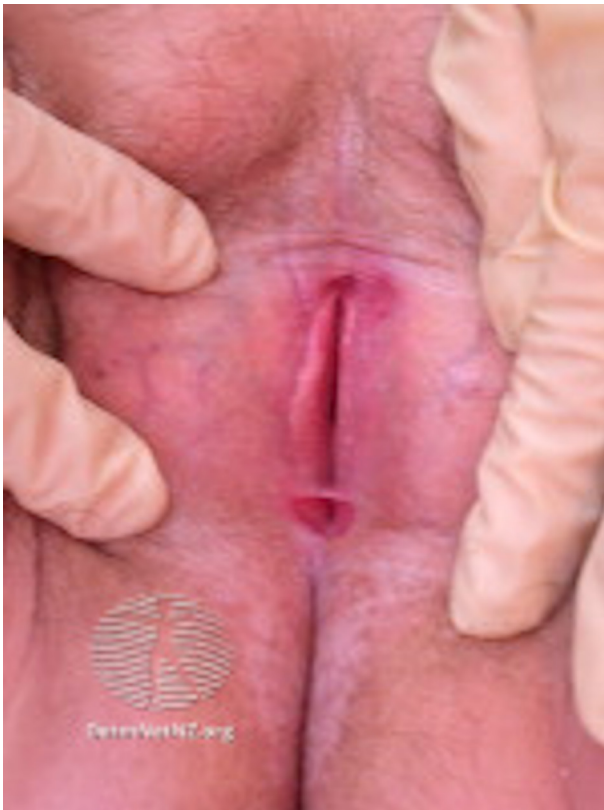

Figure 1 Posterior labial fusion (copyright of DermNet New Zealand trust).

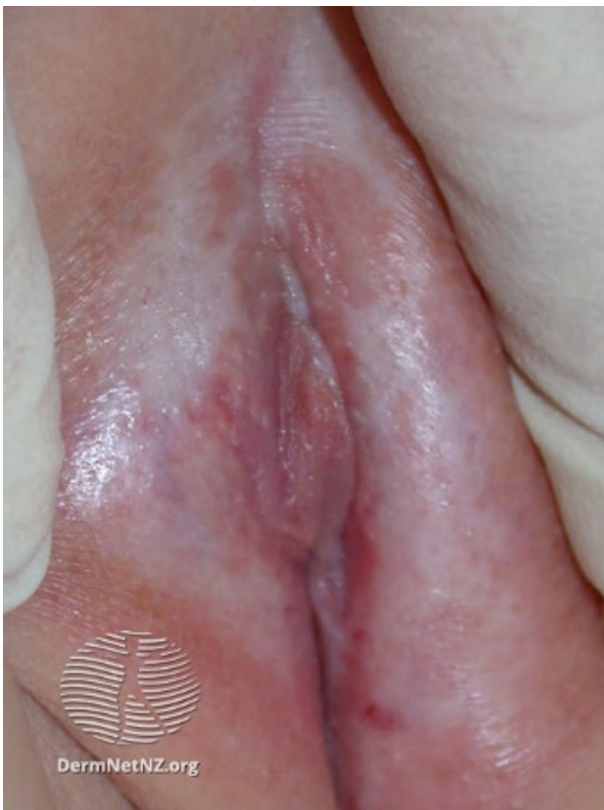

Figure 2 Lichen sclerosus et atrophicus (copyright of DermNet New Zealand trust).



1	Preadolescent	Preadolescent
2	Sparse, lightly pigmented, straight medial border of labia	Breast and papilla elevated as small mound, areolar diameter increased.
3	Darker, beginning to curl, increased amount	Breast and areola enlarged no contour separation
4	Coarse, curly abundant but amount less than in adult	Areola and papilla form secondary mound
5	Adult feminine triangle, spread to medial surface of thighs	Mature; nipple projects, areola part of general breast contour

Figure 3 Female Tanner staging of physical sexual development (adapted from WHO and https://en.wikipedia.org/wiki/Tanner_scale#/media/File:Tanner_scale-female.svg).

Urethral prolapse can present as apparent vaginal bleeding with a visible palpable red mass of friable tissue.² It is usually associated with dysuria, haematuria or vaginal discharge. It occurs more frequently in Black pre-pubertal girls between the ages of 4 and 8 years. Contributing factors include oestrogen deficiency, urinary tract infections, trauma, increased intra-abdominal pressure and anatomical defects including female genital mutilation.⁴ A paediatric urology opinion may be required.

Vaginal foreign bodies can present with vaginal bleeding, foul-smelling discharge, itching, redness, dysuria or abdominal pain.² One of the most common foreign bodies found is toilet paper.⁵ Foreign bodies can be inserted by the girl herself or someone else and CSA must always be considered. Examination under anaesthetic (EUA) with vaginoscopy/cystoscopy may be required.

Although rare, vaginal bleeding may be due to vaginal, cervical or ovarian tumours and if suspected, prompt investigation is required.²

In the context of hormonal causes of premature menarche, it is helpful to establish the presence

	Visible cause	No visible cause
Hormonal		<i>Endogenous causes</i> such as Precocious puberty, congenital adrenal hyperplasia, primary hypothyroidism <i>Exogenous causes</i> such as hormone use/maternal hormone
Infectious	Genital warts, herpes	Infectious vulvovaginitis, Sexually transmitted infections (Chlamydia, Gonorrhoea), Non-sexually transmitted infections (<i>β</i> Haemolytic Strep/ <i>S.aureus</i>)
Inflammatory	Autoimmune disease (lichen sclerosis <i>atrophicus</i> , lichen simplex <i>chronicus</i>)	Poor hygiene, chemical irritants
Trauma	Foreign body, accidental injury, sexual abuse, female genital mutilation (FGM)	Foreign body, accidental injury, sexual abuse
Urological	External neoplasm, urethral prolapse, peri-urethral cyst	Urinary tract infection, internal neoplasm <i>e.g. Wilms' tumour</i>
Neoplasm	Gonadal stromal tumours, benign tumours (polyps, <i>ano</i> -genital warts)	
Other	Haemangioma, nappy rash	Blood dyscrasia, fabricated illness, McCune Albright syndrome, Benign prepubertal vaginal bleeding

Figure 4 Causes of apparent vaginal bleeding by examination finding. Adapted from Nayak 2014¹⁴ and Söderström 2016.⁸

or absence of associated signs of normal pubertal sequence.² The presence and development of secondary sexual characteristics in the normal pubertal pattern (figure 3) may suggest a diagnosis of central precocious puberty or McCune Albright syndrome.⁶ Serum gonadotrophin and oestradiol levels may assist in making the diagnosis.² The presence of pubertal signs not developing in the normal pattern with premature menarche could be due to congenital adrenal hyperplasia (ovarian cysts) or hypothyroidism (ovarian cysts, short stature).² If a hormonal disorder is suspected, referral for a full assessment of pubertal status, including pelvis ultrasound and growth measurements, should be made to a paediatric endocrinologist. It is important to consider neonatal hormone withdrawal bleeding in an infant <1 month of age.⁶

Isolated premature menarche or benign pre-pubertal vaginal bleeding can be considered in isolated or recurrent vaginal bleeding, if no evidence of progressive secondary sexual characteristics and all other causes have been excluded. It is uncommon and self-limiting.⁷

Traumatic causes of apparent vaginal bleeding, which can result in abrasions or lacerations, can be accidental or a consequence of CSA. Accidental trauma to the genital area is common and usually minor, but the clinician must maintain a high index of clinical suspicion for physical or sexual abuse.⁸ Injuries can be non-penetrating blunt trauma, such as straddle injuries where the soft tissues (clitoris, labia urethra) are compressed against the pelvis, or less commonly penetrating trauma (including impalement) where external and internal genital structures as well as deeper pelvic organs may be affected.^{2,5} Typically, in straddle injury, an asymmetrical laceration of the interlabial sulcus or vestibule is seen. In the absence of a clear, witnessed account of an accident, injuries affecting the hymen or posterior fourchette are particularly suspicious

Box 1 Case study—sometimes things are as they seem

A 3-year-old girl presented on Christmas Eve with profuse apparent vaginal bleeding. Parents offered the explanation that she sat on a toy in the bath. Fluid resuscitation and tranexamic acid were required to stabilise her condition. With the application of pressure dressings, the bleeding ceased. External inspection by senior ED medical team and surgical team of the ano-genital region was unremarkable. Further examination under anaesthetic was required and revealed three internal vaginal lacerations while no external injuries were noted. The Sexual Assault Referral Centre was contacted given the severity of the injury and unusual history. The parents were consistent with their detailed explanation of mechanism of injury. Given the child's unstable condition, the Forensic Medical Examiner attended the hospital. All belongings were retained as evidence. Police searched the home and retrieved a Triceratops dinosaur toy from the bath (figure 7). On closer inspection of the toy, it was agreed that the injuries found were consistent with the position of the horns on the toy. Deliberate penetration with the object either due to CSA or self-penetration were considered but excluded after extensive discussions with parents and evaluation of the home environment and no further safeguarding pathways were pursued.

for CSA although CSA can affect any genital or anal tissue.² Clinicians should be alert to the possibility of female genital mutilation which is illegal in the UK and refers to any procedures which result in intentional change/injury to the genital organs for non-medical reasons. WHO have developed a classification system (<https://www.who.int/sexual-and-reproductive-health/types-of-female-genital-mutilation>).

Box 1 highlights an interesting case.

If sexual abuse is suspected in the context of ano-genital bleeding, then forensic examination, as early as is practicable, is recommended to detect associated signs including erythema, oedema, bruising, abrasions and genital lacerations² and collect DNA for forensic analysis.⁹

When determining the cause of vaginal bleeding clinically, it may be helpful to consider whether or not there is an associated visible lesion⁴ (figure 4).

Figure 4 summarises many of the causes of apparent PV bleeding based on examination findings in the pre-pubertal girl.

IMPORTANT ASPECTS OF HISTORY AND EXAMINATION

The first priority in any girl with apparent vaginal bleeding is to ensure she is haemodynamically stable and appropriately resuscitated before proceeding with a thorough history and examination.

HISTORY

The following offers a useful initial approach to history-taking in apparent vaginal bleeding.⁵

Ask about the nature of the bleeding, ie, spotting or heavy, duration and frequency if recurrent.

Enquire about associated symptoms including itch, discharge or urinary symptoms.

Are there signs of puberty?

Vulval irritation and erythema are common, non-specific and usually benign.¹⁰ Vaginal discharge is common, usually benign and usually culture negative; however, if persistent, important causes to exclude include foreign body particularly if offensive. Sexually Transmitted Infections (STIs) also need to be excluded.²

It is useful to ask about the presence of secondary sexual characteristics such as breast development. Precocious puberty tends to present with rapid growth, skeletal maturation and breast development.¹¹ Figure 3 provides a useful reminder of Tanner staging of pubertal development. If the vaginal bleeding is associated with café-au-lait spots or there is a history of previous fractures suggesting fibrous bone dysplasia, consider McCune Albright syndrome.¹²

If injury has been reported, the following approach to history-taking is helpful.

WHO?

- ▶ Provided history?
- ▶ Was present when history provided?
- ▶ Witnessed injury (child/adult and their relationship to child)?

WHAT?

- ▶ Was child doing before and at time of injury?
- ▶ What happened/caused injury? (any objects involved)
- ▶ Happened after the injury? Including any actions taken

WHERE?

- ▶ Did injury occur?

WHEN?

- ▶ Did injury occur?

WHY?

- ▶ A delay in seeking medical attention? (if applicable)

Preceding history can provide valuable clues to aetiology such as trauma, ingestion/topical application of oestrogen-containing medicines or recent infections.⁵

The possibility of inflicted physical injury or sexual abuse can often seem like the ‘elephant in the room’ both for parent/carer and clinician. It can be addressed by directly asking if there have been any disclosures of abuse from the child or unusual behaviours noted. Alternatively, it might be helpful to say “When we see a child with a genital problem, we always have to consider the possibility of sexual abuse; do you have any worries/concerns about that?”. If the child is of an appropriate developmental stage, they can be asked “Is there anything you think might be causing the bleeding?” and it is important that they are routinely spoken to on their own also.

Box 2 RED FLAGS for inflicted injury

- ▶ Allegation/disclosure of physical/sexual abuse
- ▶ Delayed presentation
- ▶ No explanation for injury/history inconsistent with injury/ changing history
- ▶ Injuries of hymen or posterior fourchette unless clear history of accidental penetrating injury

If an allegation or disclosure of abuse is made by child/parent/carer, the child should be assessed directly by the Sexual Assault Referral Centre (SARC) paediatrician/Forensic Medical Examiner as soon as immediate health needs are addressed. They must be referred to police and social services. A careful and thorough safeguarding history is essential to establish the living arrangements and social circumstances of the child and to establish whose care they were in. Establish who holds parental responsibility and whether there is any previous or current contact with social services.

Features of history and examination that raise concern about inflicted injury are highlighted in box 2.

EXAMINATION

The best position in which to examine the prepubescent external genitalia and outer 1/3 of vagina is ‘knee-to-chest’ or supine ‘frog-leg’ (supine with soles of feet together and knees apart to expose the perineum), perhaps on parent/carer’s lap if young child.^{2 13} Adequate lighting is essential for an optimal examination and box 3 highlights other important considerations.¹⁴ The labia majora should be gently separated to view the vestibule and hymenal orifice for any abnormality, recent or old injuries.² Lateral traction using thumb and forefinger will provide a good view of the hymen, upward traction will show the urethra and downward traction will display posterior hymen and fossa navicularis.² Prone knee-to-chest position also provides a good view of the posterior hymen.²

Box 3 KEY CONSIDERATIONS during INITIAL INSPECTION of ano-genital area

- ▶ Gain child/parental consent
- ▶ Arrange to have a chaperone
- ▶ Should be performed urgently by the most SENIOR member of medical staff available.
- ▶ Frequent re-examination should be avoided where possible
- ▶ If sexual abuse is suspected, forensic samples should ideally be taken within the forensic guidelines by forensic team⁹

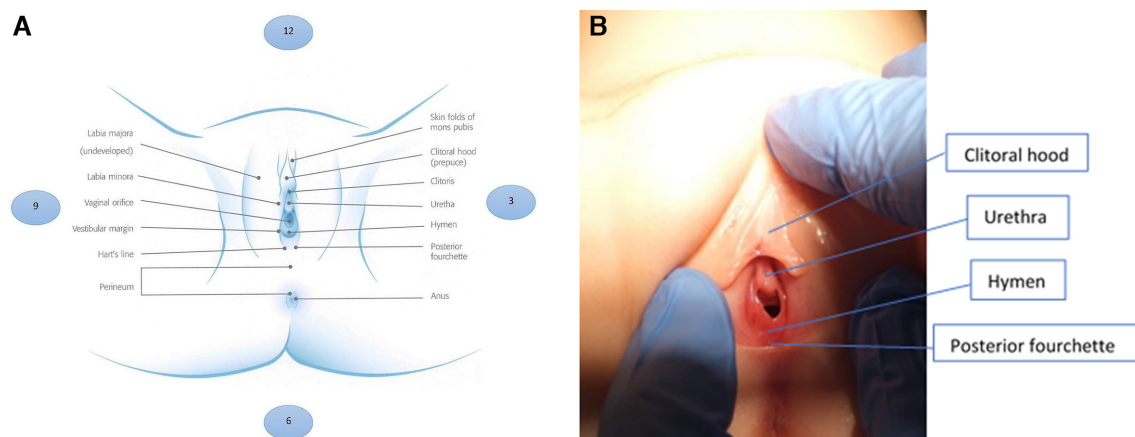


Figure 5 (A) Anatomy of female external genitalia with clock notation. Guideline for medical assessment of children presenting with blood noted in the underwear—the Rowan Sexual Assault and Referral Centre (SARC), Antrim Area Hospital. (B) Photograph of female external genitalia (parental consent obtained).

When inspecting the female ano-genital region, it is useful to systematically assess the appearance of the (figure 5A,B)

1. Labia majora and minora
2. Clitoral hood (prepuce)
3. Clitoris
4. Hymen
5. Vaginal opening
6. Vestibule
7. Posterior fourchette
8. Anus

Note the presence of^{2 5}

- ▶ Erythema
- ▶ Bruising
- ▶ Swelling
- ▶ Abrasions
- ▶ Lacerations
- ▶ +/- active bleeding and/or discharge
- ▶ Rashes, skin changes/lesions

This should be documented on an appropriate body diagram using a clock face notation for location, complete with patient details.²

The condition of the child's skin and genitalia should be noted, for example, whether the skin is

fragile and prone to cracking as well as personal hygiene.² Any signs of neglect (hair, teeth, cleanliness, skin infestations) should be noted. Any evidence of abnormal bruising tendency, piercings and so on should be documented.² The presence of any birthmarks or café-au-lait spots should be noted. Growth parameters should be documented. The child should be assessed for evidence of chronic disease which may predispose to coagulopathy, for example, liver disease or the presence of a goitre suggesting thyroid disease. The child's underwear should also be examined. It is important to remember that a normal examination does not exclude sexual abuse as many injuries heal without leaving evidence therefore maintain a high index of clinical suspicion.²

IMPORTANT ANATOMY

To recognise an ano-genital abnormality in a pre-pubertal girl, clinicians need to be able to confidently recognise normal anatomy. The vulva of a pre-pubertal girl differs from that of a girl post-menarche. Vaginal epithelium in girls pre-menarche is thin and appears red due to lack of oestrogen.¹³ Figure 5A,B provides a useful reminder of the anatomy of external female genitalia. The posterior fourchette is the point at which the labia meet at the back. The fossa navicularis is the boat-shaped depression at the posterior vestibule (figure 5A). It is useful to be aware that the hymen can be different shapes including annular, crescentic, fimbriated and funnel-shaped.

*See box 4 for actions if child being referred to Sexual Assault referral Centre for further assessment.

Box 4 Actions if CHILD being referred to sexual assault referral centre for further assessment

- ▶ Preserve underwear/nappy as evidence
- ▶ If possible, use medical photography to take a photograph of the underwear/nappy
- ▶ Advise carer not to wash child
- ▶ Make child nil by mouth in case examination under general anaesthetic required
- ▶ Document if child passes urine or stools
- ▶ Formal referral by responsible Consultant to Social Services and Police followed up in writing according to local guidance (person with parental responsibility should be informed of this)

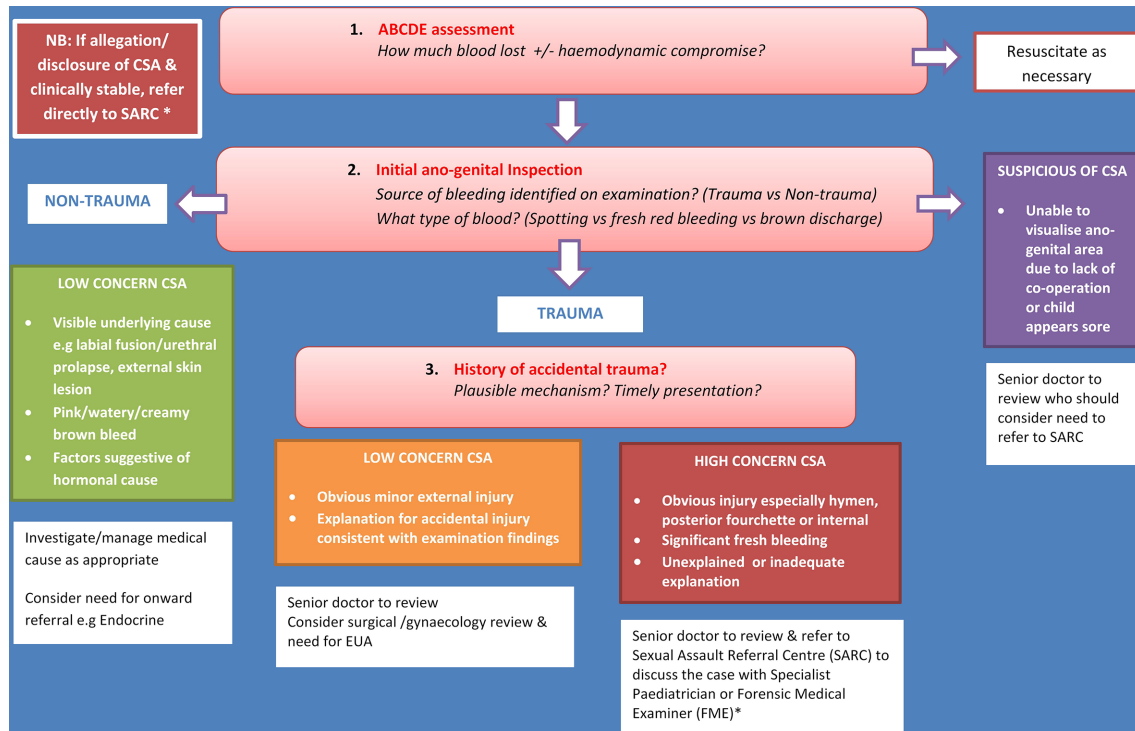


Figure 6 Flowchart summarising approach to apparent vaginal bleeding in the pre-pubertal girl. CSA, child sexual abuse; EUA, examination under anaesthesia.

HOW TO INVESTIGATE AND MANAGE APPARENT VAGINAL BLEEDING?

Examination under anaesthetic (EUA) or vaginoscopy/colposcopy may be indicated if vaginal bleeding is suspected to be secondary to trauma and the extent or location of the injury cannot be determined on initial inspection. It should also be considered when attempting to exclude a foreign body, tumour or indeed if no apparent cause for bleeding is found.⁸

Other investigations are guided by history and clinical findings. Urine microscopy and culture may help exclude haematuria. Blood tests such as FBC and coagulation screen can help exclude a clotting abnormality. A swab for microscopy, culture and sensitivity in the presence of discharge may be useful particularly if offensive. Imaging such as pelvic ultrasound, CT or MRI may help detect foreign bodies, tumours or cysts.⁵ Endocrine investigations such as TFTs, LH, FSH, oestradiol and prolactin may be appropriate if precocious puberty is suspected and referral to a Paediatric Endocrinologist may be indicated.

Management is also guided by aetiology.

In non-specific vulvovaginitis, education about good hygiene practices including wiping front to back and avoidance of perfumed bathing products can be beneficial.⁵ If culture positive, appropriate topical or systemic antimicrobials may be indicated.

In minor trauma, salt baths and topical local anaesthetic gel may be helpful. In more significant trauma such as the case study described, the surgical team may need to be involved in care.

If inflicted injury is suspected, discuss with local SARC and complete actions in box 4. The flowchart in figure 6 summarises the approach to apparent vaginal bleeding in the pre-pubertal girl.

CONCLUSION

Confirmed vaginal bleeding in a pre-pubertal girl is always abnormal and requires comprehensive assessment to determine the cause. Clinicians should practise within the limits of their competence. The possibility of child sexual abuse and the need for examination by a specialist paediatrician or Forensic Medical Examiner at SARC should always be considered.



Figure 7 Triceratops toy found in bath (parental consent obtained).

Test your knowledge

- Causes of vaginal bleeding in the pre-pubertal child DO NOT include:
 - McCune Albright syndrome
 - Sexual abuse
 - Meckel's diverticulum
 - Vulvovaginitis
- At which Tanner stage does breast development commence?
 - Stage 1
 - Stage 2
 - Stage 3
 - Stage 4
- Red flags for inflicted injury include:
 - Immediate presentation
 - History consistent with injury
 - No allegation/disclosure of abuse
 - Hymenal/posterior fourchette injuries in absence of clear history of accidental penetrating trauma
- The boat-shaped depression at the posterior vestibule is called:
 - Posterior fourchette
 - Hymen
 - Fossa navicularis
 - Median raphe
- If child is being referred to Sexual Assault Referral Centre, the following action is appropriate:
 - Preserve underwear/nappy
 - Wash the child
 - Don't photograph
 - Let the child eat and drink normally

Answers to the quiz are at the end of the references.

Twitter Julie-Ann Maney @julieannmaney

Contributors J-AC researched and wrote the article. It was reviewed and edited by J-AM and AL.

Funding The authors have not declared a specific grant for this research from any funding agency in the public, commercial or not-for-profit sectors.

Competing interests None declared.

Patient consent for publication Parental/guardian consent obtained.

Provenance and peer review Commissioned; externally peer reviewed.

REFERENCES

- Radford L, Susana C, Christine B, *et al.* *Child abuse and neglect in the UK today*. London: NSPCC, 2011.
- Royal College of Paediatrics and Child Health (RCPCH). The physical signs of child sexual abuse, 2015. Available: https://www.rcpch.ac.uk/sites/default/files/2018-02/physical_signs_of_child_sexual_abuse_-_summary_of_changes_by_chapter.pdf [Accessed 12 Apr 2019].
- Garden AS. Vulvovaginitis and other common childhood gynaecological conditions. *Arch Dis Child Educ Pract Ed* 2011;96:73–8.
- Lang ME, Darwish A, Long AM. Vaginal bleeding in the prepubertal child. *CMAJ* 2005;172:1289–90.
- Holliday K, Agwu JC. Vaginal bleeding in the pre-pubertal child. *Paediatr Child Health* 2018;28:144–8.
- Kondamundi NP *et al.* Prepubertal girl with vaginal bleeding. *J Emerg Med* 2014;46:7769–71.
- Nella AA, Kaplowitz PB, Ramnitz MS, *et al.* Benign vaginal bleeding in 24 prepubertal patients: clinical, biochemical and imaging features. *J Pediatr Endocrinol Metab* 2014;27:821–5.
- Söderström HF, Carlsson A, Börjesson A, *et al.* Vaginal bleeding in prepubertal girls: etiology and clinical management. *J Pediatr Adolesc Gynecol* 2016;29:280–5.
- Faculty of Forensic and Legal Medicine. Recommendations for the collection of forensic specimens from complainants and suspects, 2019. Available: <https://fflm.ac.uk/wp-content/uploads/2019/01/Recommendations-for-the-collection-of-forensic-specimens-from-complainants-and-suspects-Jan-2019.pdf> [Accessed 19 Apr 2019].
- Jacobs AM, Alderman EM. Gynecologic examination of the prepubertal girl. *Pediatr Rev* 2014;35:97–105.
- Pinto SM, Garden AS. Prepubertal menarche: a defined clinical entity. *Am J Obstet Gynecol* 2006;195:327–9.
- Merckx M, Weyers S, Santegoeds R, *et al.* Menstrual-like vaginal bleeding in prepubertal girls: an unexplained condition. *Facts Views Vis Obgyn* 2011;3:267–70.
- McCaskill A, Inabinet CF, Tomlin K, *et al.* Prepubertal genital bleeding: examination and differential diagnosis in pediatric female patients. *J Emerg Med* 2018;55:e97–100.
- Nayak S, Witchel SF, Sanfilippo JS. Vaginal foreign body: a delayed diagnosis. *J Pediatr Adolesc Gynecol* 2014;27:e127–9.

Answers to the multiple choice questions

- C. Meckel's diverticulum.
- B. Stage 2.
- D. Hymenal/posterior fourchette injuries in absence of clear history of accidental penetrating trauma.
- C. Fossa navicularis.
- A. Preserve underwear/nappy.