



Fifteen-minute consultation on limiting investigations in the fainting child

Michael Harris, Frances Bu'Lock

Department of Paediatric Cardiology, University Hospitals Leicester NHS Trust, Leicester, UK

Correspondence to

Dr Michael Harris, Paediatric Cardiology, University Hospitals Leicester NHS Trust, Glenfield Hospital, Groby Road, Leicester LE3 9QP, UK; michaeljharris@doctors.org.uk

Received 6 April 2015

Revised 24 June 2015

Accepted 2 July 2015

Published Online First

22 July 2015

ABSTRACT

Syncope can be a dramatic and frightening experience for the patient and onlookers. It can also be a confusing area for doctors, with a lack of diagnostic certainty and a differential that ranges from the completely benign to the life-threatening. This is a tricky area for clinicians, who can find it difficult to reassure their patients and their families. The aim of this article is to present a clear scheme for appropriate investigation and referral of paediatric patients with syncope. The aim of investigations in such cases should be to confirm or exclude serious, life-threatening causes of syncope.

Syncope can be a dramatic and frightening experience for the patient and onlookers. It can also be a confusing area for doctors, with a lack of diagnostic certainty and a differential that ranges from the completely benign to the life-threatening. Referrals for tertiary opinions occupy a lot of time in paediatric cardiology and neurology clinics (5.8% of paediatric cardiology clinic referrals in a 1 year period in a US Centre).¹ Recent well publicised events on the sports field have added to the anxiety. The primary concern is generally whether or not the syncopal episode is an event that precedes sudden cardiac death or signals the onset of epilepsy. Although sudden cardiac death is rare (0.6–8.5 deaths/100 000 patient years)¹ it occupies a disproportionate amount of the public and professional mind.

This is a tricky area for clinicians, who can find it difficult to reassure their patients and their families. The aim of this article is to present a clear scheme for appropriate investigation and referral of paediatric patients with syncope. The aim of investigations in such cases should be to confirm or exclude serious, life-threatening causes of syncope.²

WHAT IS SYNCOPE?

Syncope is a transient, but complete, loss of consciousness (with associated loss of muscle tone) due to global cerebral hypoperfusion.³ By definition:

- ▶ It is of rapid onset
- ▶ It is of short duration
- ▶ Recovery is
 - quick
 - spontaneous
 - complete

Therefore, by definition, this excludes:

- ▶ Falls, which usually do not involve loss of consciousness
- ▶ States of altered, but not loss of, consciousness
- ▶ Coma, which, by definition, is not transient loss of consciousness
- ▶ Aborted sudden cardiac death
- ▶ Epileptic seizures
- ▶ Psychogenic causes
- ▶ 'Near' syncope, in which patients do not experience loss of consciousness, but can have several symptoms including lightheadedness, etc.

WHAT CAUSES SYNCOPE?

Syncope can be divided on an aetiological basis, into

- ▶ Syncope due to cardiac causes
- ▶ Syncope due to reflex mechanisms, which includes vasovagal syncope
- ▶ Orthostatic hypotension.

WHY DOES SYNCOPE HAPPEN?

Syncope occurs when the systolic blood pressure (BP) falls below around 60–70 mm Hg,² although this exact figure is age-related.

BP is the product of cardiac output and systemic vascular resistance. Therefore, anything that affects one or both of these determinants will cause an alteration in BP. Examining cardiac output and systemic vascular resistance in turn.



To cite: Harris M, Bu'Lock F. Arch Dis Child Educ Pract Ed 2016;**101**:26–30.

Cardiac output can be affected by:

- ▶ Cardiac mechanisms
 - Changes in heart rate and rhythm
 - Structural heart problems, for example, aortic stenosis
- ▶ Reflex (nervous) mechanisms
 - Slow heart rate due to reflex nervous activity (vagal)
- ▶ Orthostatic mechanisms
 - Inadequate venous return

Systemic vascular resistance can be affected by:

- ▶ Reflex mechanisms
 - Vasodilation due to inappropriate reflex activity
- ▶ Orthostatic mechanisms
 - Impairment, due to a variety of primary and secondary causes, of the autonomic nervous system
- ▶ Generally cardiac factors do not affect systemic vascular resistance (figure 1).

WHAT CAUSES CARDIAC SYNCOPE?

The serious, life-threatening causes of syncope are generally cardiac in nature. Cardiac causes of syncope result in low cardiac output. Cardiac syncope may be due to:

- ▶ Electrical disturbances (arrhythmias)
 - Bradycardia, which is uncommon in children
 - Sinus node dysfunction
 - AV node dysfunction
 - Implanted device (eg, pacemaker) malfunction
 - Tachycardia
 - Supraventricular
 - Ventricular
 - Long QT syndrome⁴ (see figure 2)
 - Brugada syndrome (see figure 3)
 - Catecholaminergic polymorphic ventricular tachycardia (see figure 4)
 - Drug-induced, which may act via the above mechanisms.
- ▶ Structural cardiac problems
 - Hypertrophic cardiomyopathy
 - Dilated cardiomyopathy
 - Arrhythmogenic right ventricular cardiomyopathy
 - Coronary artery anomalies

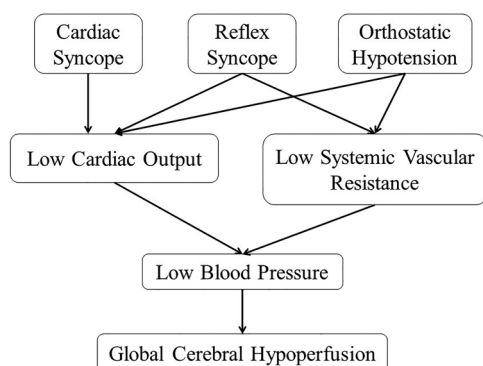
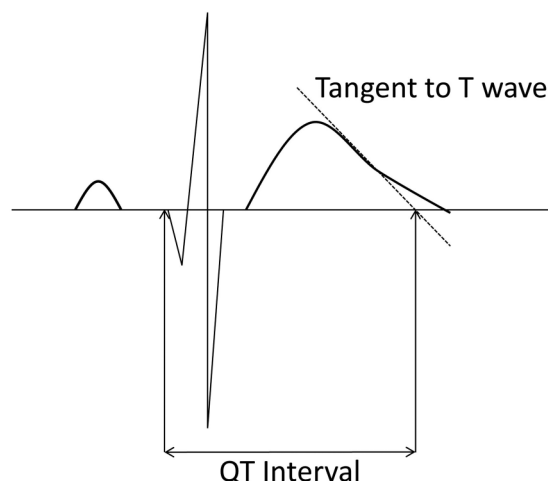


Figure 1 Mechanisms of syncope.



Bazett's Formula: $QTc = QT / \sqrt{PR}$

Figure 2 ECG of long QT syndrome showing the 'Tangent' method for measuring QT interval.

- For example, left coronary artery coursing between the aorta and the pulmonary artery; anomalous origin of the left coronary artery from the pulmonary artery
- Aortic stenosis, resulting in an obstructed left ventricular outflow tract
- Myocarditis
- Pulmonary hypertension, although there is usually a history of exertional dyspnoea rather than syncope in this condition
- Cardiac tumours

The non-life-threatening causes of syncope, therefore, fall into the remaining two categories, namely:

- ▶ Reflex syncope, which includes 'vasovagal' episodes
- ▶ Orthostatic hypotension.

HOW SHOULD YOUNG PEOPLE WITH SYNCOPE BE ASSESSED?

Assessment begins with an accurate history to confirm syncope, to identify a possible causal mechanism (cardiac, reflex, orthostatic—see box 1 for further characteristics) and to ascertain any relevant background information, including family history. Assessment should

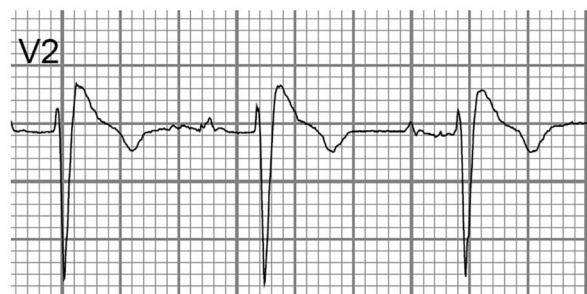

Figure 3 ECG showing characteristic appearance of ST segment in Brugada syndrome.

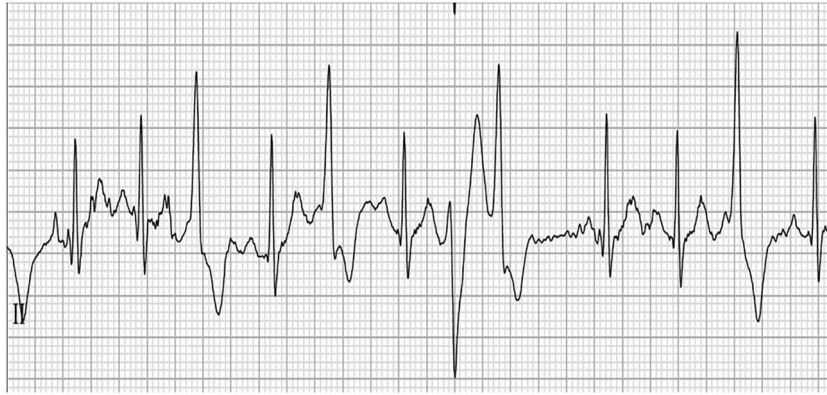

Figure 4 ECG showing appearances of polymorphic ventricular complexes on exercise testing in a patient who is β -blocked and known to have catecholaminergic polymorphic ventricular tachycardia.

continue with physical examination. For completeness, BP can be recorded at this time. A 12-lead ECG should be performed as the initial baseline investigation in syncope. On the basis of these initial actions, further investigations or onward referral can be considered.

Studies have confirmed that the sensitivity of screening using history, examination and 12-lead ECG findings can be 100% sensitive for the cardiac causes of syncope.^{1 5}

HISTORY

The mainstay of diagnosis is in the history. First and foremost, loss of consciousness must be confirmed. Many patients have funny turns but not true syncope. The event should be transient, of rapid onset and short duration. There should be loss of postural tone. Recovery should be spontaneous, complete and without sequelae. Lack of an eyewitness can make diagnosis more challenging. If not all of these features can be confirmed, then it will be necessary to exclude other causes of loss of consciousness. Seizures may be a sequelae of syncope. However, it is important to note that a number of people diagnosed with epilepsy may in fact have a cardiac cause of syncope. In a study from New Zealand, several patients had a delayed diagnosis

of long QT syndrome and were instead diagnosed as epileptic. On review, several of these patients had had baseline ECGs that were abnormal, but because the corrected QT had been miscalculated initially, the diagnosis had been missed.⁶ The corrected QT interval should be calculated using Bazett's formula, which corrects for heart rate. The end of the T wave can be difficult to define, but using the 'Tangent' method, this uncertainty is much reduced⁴ (see figure 2).

Once syncope is confirmed, the history must seek to elucidate the possible cause, that is, cardiac, reflex or orthostatic. A good history of the event, the situation and position of the patient before, during and after the event should be sought (see boxes 1–4). If mobile phone or video footage of the event exists, then this is often invaluable.

In the background, a family history of sudden death, arrhythmias at a young age (less than 40 years) and previous cardiac disease should be confirmed or excluded. Of note, a study from the Netherlands published in 2009 showed that patients with long QT syndrome were significantly more likely to have a family history of syncope and sudden death.⁷ Neurological disorders, including epilepsy and other neurodisabilities, and metabolic problems, principally diabetes, should be sought. Medications, including vasoactive substances such as diuretics, and other drugs (including of abuse) should be assessed.

Box 1 Classical premonitory symptoms for syncope²

- Often evolving, gradual, progressive
- ▶ Nausea
- ▶ Blurred/tunnel vision
- ▶ Hearing changes (muffled, buzzing)
- ▶ Dizziness
- ▶ Light-headedness
- ▶ Sweating
- ▶ Pallor
- ▶ Cold, clammy skin
- ▶ Weakness, tremulousness

Box 2 Features suggestive of reflex (neurally mediated) syncope^{2 3 8}

- ▶ Nausea (unique to non-arrhythmogenic syncope)
- ▶ Vomiting
- ▶ After an emotionally stressful event
- ▶ Following prolonged standing in a hot, crowded area
- ▶ During or after a meal
- ▶ After (not usually during) exercise
- ▶ With head rotation

Box 3 Features suggestive of syncope due to orthostatic hypotension³

- ▶ Following standing from supine, sitting or squatting position
- ▶ Standing after exercise
- ▶ Prolonged standing in a hot environment
- ▶ Secondary to commencement of vasoactive medications

RED FLAGS FOR CARDIAC SYNCOPE

More specifically, 'Red Flag' features in the history significant for a *cardiac* cause of *syncope* are shown in [box 4](#). Some investigators⁸ have found that dizziness is a symptom in patients with arrhythmogenic (cardiac) syncope. However, nausea appears to be unique to non-arrhythmogenic syncope.

Reflex syncope is suggested by typical triggers and typical prodromal symptoms (see [boxes 1 and 2](#)). The European Society of Cardiology³ further subdivides reflex syncope into vasovagal, situational, carotid sinus and atypical syncope.

Vasovagal syncope occurs secondary to emotional stressors or the sight of blood, or a painful stimulus, among others, but can also occur secondary to orthostatic stress. For example, this would include syncope on standing from a lying or squatting position.

Situational syncope might occur secondary to ordinary activities such as stretching, hair brushing, coughing, sneezing, micturition, swallowing (especially cold liquids), defaecation, following meals, after prolonged standing, in warm or crowded environments,⁹ or immediately after (not during) strenuous exercise.

Carotid sinus syncope is presumably secondary to carotid sinus massage causing vagal stimulation. This might occur when wearing tight collars or neckties.

Atypical forms of reflex syncope also occur. These are, by definition, rather difficult to define, but occur without apparent triggers or with an atypical presentation.

Box 4 Red flag symptoms for cardiac syncope^{3 7 8}

- ▶ During exertion
- ▶ When supine
- ▶ When asleep
- ▶ Immediately following sudden onset palpitations
- ▶ Exertional chest pain prior to syncope
- ▶ In a swimming pool
- ▶ Secondary to auditory stimuli
- ▶ Without warning (no prodrome)
- ▶ Structural heart disease
- ▶ Family history of:
 - Sudden death
 - Congenital arrhythmias

Orthostatic hypotension (see [box 3](#)) can be thought of as a spectrum of several conditions, some of which are more common in adults and the elderly.³ While the pathophysiological mechanisms are different, there are similarities in clinical symptomatology between reflex syncope and orthostatic hypotension. In some situations, orthostatic hypotension can trigger reflex vasovagal mechanisms, causing syncope. This occurs more commonly in younger patients than in the older population. Initial hypotension, causing symptoms of a 'head rush', is common in adolescents upon standing, although syncope is rare. If syncope due to orthostatic hypotension occurs in the paediatric population, it is more likely due to volume depletion in the context of haemorrhage, diarrhoea or vomiting. Drugs, including vasodilators and diuretics, may induce hypotension. Alcohol should not be forgotten, although intoxication is a more likely cause for apparent syncope. Apart from this, primary and secondary autonomic failure is more common in adults.

POSTURAL ORTHOSTATIC TACHYCARDIA SYNDROME

Syncope is not a part of this increasingly recognised syndrome.¹⁰ Postural orthostatic tachycardia syndrome is characterised by orthostatic symptoms (ie, light-headedness, dizziness, vision changes, nausea), which occur on a daily basis and, for diagnostic purposes, should have persisted for several months, coupled with sympathetic activation (excessive heart rate, palpitations, chest pain). In contrast to true orthostatic intolerance, orthostatic hypotension is absent.¹¹ In this context, excessive heart rate in children and teens is defined as an increase above baseline of greater than 40 bpm. Some investigators use a head-up tilt test as part of their diagnostic protocol. The ECG should show sinus rhythm. Symptoms should improve with recumbence. Female patients outweigh men by 3–4:1, with a high preponderance of chronic fatigue and gastrointestinal dysfunction as comorbidities. A variety of treatments, including medications, are available to treat patients with postural orthostatic tachycardia syndrome, but one of the keys is exercise reconditioning.

LIMITING INVESTIGATIONS IN YOUNG PEOPLE WITH SYNCOPE

Cardiac causes of syncope can most likely be excluded with high sensitivity with appropriate history taking, clinical examination and a 12-lead ECG. Further investigations are probably inappropriate. It may be helpful, and indicated, to obtain an ambulatory ECG prior to referral to, or at the suggestion of, a paediatric cardiologist. However, ambulatory ECG monitoring has a low yield³ for capturing arrhythmia, of the order of 14%¹ in some studies, even in those subsequently shown to have cardiac syncope. In the same

study, 15% of patients reported symptoms that had no correlation on ambulatory ECG monitoring. The low yield is likely due to the relative infrequency of arrhythmia events, which are too infrequent to occur contemporaneously with monitoring.

Further investigations that may be carried out by a cardiologist may include an echocardiogram, in the context of an abnormal clinical cardiovascular examination, exertional syncope or family history of heart muscle disease. In cases of exertional syncope, an echocardiogram is probably warranted to exclude such rare anatomical anomalies as anomalous origin of the left coronary artery from the pulmonary artery. The diagnostic yield of echocardiography is low, as with ambulatory ECG monitoring, less than 50% in some studies, even in those with cardiac syncope. In one study from several years ago,¹² the sensitivity of echocardiography for detecting a cardiac cause of syncope was 18%.

In the case of exertional symptoms or startle-related syncope, exercise testing is mandated, as conditions such as catecholaminergic polymorphic ventricular tachycardia cannot be detected on a resting ECG.¹³

Other, further investigations might include:

- ▶ Longer-term ambulatory monitoring, dependent upon symptom type and frequency. Event monitors (patient activated) generally have no role in syncope, but are useful in palpitations
- ▶ Implantable loop recorder
- ▶ Invasive electrophysiological studies, although these are rarely required
 - Tilt-table testing is not particularly useful in the paediatric population, and should be left in the hands of experts. In the context of limiting investigations in fainting children, tilt testing is not usually required for excluding the life-threatening causes of syncope. It may be helpful, in the hands of experienced investigators, in discriminating between reflex syncope, orthostatic hypotension, seizure disorders and psychiatric disorders. Protocols for tilt testing are not uniform, and as children have a higher propensity to orthostatic hypotension compared with the adults for whom the protocols were designed, there is a lack of specificity inherent in this investigation.

In summary, when looking to limit investigations in the fainting child, it is important to have as clear as possible a history of the events. If syncope is confirmed, then the object is to exclude serious, potentially life-threatening, causes of syncope. These are essentially the cardiac causes of syncope.¹³

History, examination and ECG are usually sufficient to confirm benign causes of syncope, or to identify

those patients who need referral for further assessment and investigation.

Fainting in children will continue to provoke consternation, and there will always be diagnostic dilemmas. However, the vast majority of syncopal episodes in children are benign in nature, and it is satisfying and resource efficient to be able to swiftly reassure children and their parents on the basis of history, clinical examination and some rudimentary investigations.

Contributors MH researched and wrote the article. FB reviewed and edited the article.

Competing interests None declared.

Provenance and peer review Commissioned; externally peer reviewed.

REFERENCES

- 1 Tretter JT, Kavey REW. Distinguishing cardiac syncope from vasovagal syncope in a referral population. *J Pediatr* 2013;163:1618–23.
- 2 Moodley M. Clinical Approach to syncope in children. *Semin Pediatr Neurol* 2013;20:12–17.
- 3 Moya A, Sutton R, Ammirati F, *et al.* Guidelines for the diagnosis and management of syncope (version 2009). *Eur Heart J* 2009;30:2631–71.
- 4 Postema PG, De Jong JS, Van der Bilt IA, *et al.* Accurate electrocardiographic assessment of the QT interval: teach the tangent. *Heart Rhythm* 2008;5:1015–18.
- 5 Johnson ER, Etheridge SP, Minich LL, *et al.* Practice variation and resource use in the evaluation of pediatric vasovagal syncope: are pediatric cardiologists over-testing? *Pediatr Cardiol* 2014;35:753–8.
- 6 MacCormick JM, McAlister H, Crawford J, *et al.* Misdiagnosis of long QT syndrome as epilepsy at first presentation. *Ann Emerg Med* 2009;54:26–32.
- 7 Colman N, Bakker A, Linzer M, *et al.* Value of history-taking in syncope patients: in whom to suspect long QT syndrome? *Europace* 2009;11:937–43.
- 8 MacCormick JM, Crawford JR, Chung SK, *et al.* Symptoms and signs associated with syncope in young people with primary cardiac arrhythmias. *Heart Lung Circ* 2011;20:593–8.
- 9 Wieling W, Ganzeboom KS, Saul JP. Reflex syncope in children and adolescents. *Heart* 2004;90:1094–100.
- 10 Stewart JM. Common Syndromes of Orthostatic Intolerance. *Pediatrics* 2013;5:968–80.
- 11 Jarjour IT. Postural tachycardia syndrome in children and adolescents. *Semin Pediatr Neurol* 2013;20:18–26.
- 12 Ritter S, Tani LY, Etheridge SP, *et al.* What is the yield of screening echocardiography in pediatric syncope. *Pediatrics* 2000;105:1–3.
- 13 Bat T, Collins KK, Schaffer MS. Syncope during exercise: just another benign vasovagal event? *Curr Opin Pediatr* 2011;23:573–5.

Syncope Extended Matching Questions

For the following questions, pick the most likely answer from the list below:

- A. Reflex syncope
- B. Orthostatic hypotension
- C. Cardiac Syncope
- D. Epileptic seizure
- E. Near-syncope
- F. Postural Orthostatic Tachycardia Syndrome
- G. Aborted sudden cardiac death

For the possible investigations choose from the following list (there may be more than one correct answer):

- A. Blood pressure, including lying and standing
- B. 12 Lead ECG
- C. Ambulatory ECG
- D. Echocardiogram
- E. Exercise Tolerance Test
- F. Reveal Device
- G. EEG

1. A 9 year old, previously fit and well boy is walking home from school. He collapses to the floor. He requires bystander CPR and two DC shocks to be

defibrillated from VF. He is admitted to the Paediatric Intensive Care Unit, where an echocardiogram shows hypertrophic cardiomyopathy. A 12 lead ECG is suggestive of left ventricular hypertrophy.

2. A 13-year-old girl, a pupil at a high achieving all-girls school, complains of a fluttering sensation in her chest. Her chest aches a little when she has these episodes. They occur when she is standing up. Her friends have commented that she looks pale, 'like a goth'. Embarrassingly, she feels a little sweaty and light-headed during these episodes. The attacks last for 10 minutes and go off gradually. She is worried she is going to pass out, but has never actually done so.

3. A slender 14-year-old girl with no known medical problems or relevant family history has been referred to your clinic as she has had several episodes of collapse. These usually occur in the morning, when she is in the kitchen making breakfast. She feels light-headed, nauseated and dizzy. Her vision narrows like a tunnel and her hearing becomes muffled. No one has witnessed these episodes of collapse, but on a couple of occasions, her mother has heard a thud and come into the kitchen to find her daughter on the floor, looking very pale and feeling clammy. She is conscious but a little confused. She is normally back to herself after about 10 minutes. The girl describes her heart racing after these events.

She has a soft systolic murmur at the upper left sternal edge. What further investigations would you consider?

4. A 17-year-old boy is desperate to join the army and is undergoing selection trials. On one of the early morning runs, he suddenly collapses, but is back to normal within 10-15 minutes. Before he is deployed, the Army doctors want him to be assessed by a cardiologist. His stepfather's cousin died suddenly at the age of 24 whilst playing football, but no cause was ever found.

After taking a full history and in the presence of a normal cardiovascular examination, what further investigations would you undertake?

5. A 12-year-old Afro-Caribbean boy presents following an episode of collapse. Upon waking, he got up to go to the toilet and then got into the shower. Whilst in the hot shower, he began to feel dizzy, light-headed and nauseated. He stumbled from the bathroom and collapsed in his mother's arms. She carried him downstairs, where he began to come round whilst she was phoning 999. During the ambulance trip, he recovered to his normal self. He was assessed in the emergency department, where his cardiovascular examination was normal. There was no significant family history. Blood pressure was normal. However, a 12 lead ECG shows 1mm ST- (J point) elevation in leads V2 and V3, thought to be early repolarisation.

6. A 14-year-old county runner is referred to you following an episode of collapse after a competitive 800m race. He remembers being pushed hard by his main rival, but has no memory of crossing the finish line. Witnesses saw him fall to the ground and become very pale. He was sweaty. Someone had the presence of mind to put him into the recovery position. They thought that his pulse was quite slow initially and then sped up. They also noticed some short-lived symmetrical jerking of all 4 limbs.

He recovered well within 10 minutes, but was taken to the local emergency department to be checked over.

Given a normal cardiovascular examination, what further investigations would you consider?

7. A 14-year-old boy, who is exceptionally active normally, collapses to the ground at the end of a mountain biking run. Shortly before his collapse, he complained to his friends of chest pain. To them, he had the appearance of being dead and they commenced CPR. Upon the arrival of the paramedics some 20 minutes later, he was found to be in VF and required two defibrillation attempts before reverting to sinus rhythm with a good cardiac output.

In the PICU, echocardiogram was normal. A 12 lead ECG showed a short PR interval and a slurred upstroke of the proximal portion of the QRS complex.

Answers

1. Aborted sudden cardiac death. This presentation and underlying disease (Hypertrophic Cardiomyopathy) are an indication for placement of an internal cardiac defibrillator, for screening of family members and consideration of a referral to clinical geneticists.

Diagnosis: G; Investigations: D

2. This history could be consistent with Postural Orthostatic Tachycardia Syndrome, but there is some overlap with Orthostatic and Reflex mechanisms in the context of prolonged standing. Measuring heart rate or performing a 12 lead ECG on standing may aid in the diagnosis of POTS if tachycardia is present. However, there are currently no particular diagnostic criteria for this condition as yet.

Diagnosis: F; Investigations: B

3. This history is most likely consistent with reflex syncope. In the presence of a normal echocardiogram (done as clinical evidence of a murmur) and normal 12 lead ECG, this patient could be reassured and given advice on appropriate hydration and physical manoeuvres to undertake that may abort the episodes of syncope.

Diagnosis: A; Investigations: B

4. This history is concerning for a cardiac cause of syncope. However, it is possible for reflex syncope to occur during exercise. This should only be a diagnosis of exclusion following thorough investigation. Key features in the history would include: chest pain prior to collapse and a family history of sudden cardiac death or channelopathies. A 12 lead ECG is mandatory. An echocardiogram and/or further imaging would be indicated in this case to confirm the normal course of the coronary arteries. Exercise testing is mandated.

Diagnosis: C; Investigations: B, D, E

5. This history is consistent with reflex syncope, although again there may be overlap with orthostatic hypotension. The ECG changes are likely a normal variant and not pathological. Further investigation is probably not warranted, but may be required if there is sufficient anxiety on the part of the investigating doctor or the parents!

Diagnosis: A; Investigations: B

6. This history is most consistent with reflex syncope. In the absence of a significant family history, and presence of a normal cardiovascular examination and normal ECG, the patient and family could be reassured and discharged.

Diagnosis: A; Investigations: B

7. This is an example of cardiac syncope and aborted sudden cardiac death. The underlying diagnosis is consistent with Wolf-Parkinson-White syndrome (characteristic ECG changes plus symptoms). However, sudden cardiac death is only a very rare complication of this condition and especially so in the paediatric population. There are promulgated guidelines, subject to some debate, that offer guidance on when a radio frequency ablation of the accessory pathway should be offered.

Diagnosis: C and G; Investigations: In asymptomatic WPW, C and E